

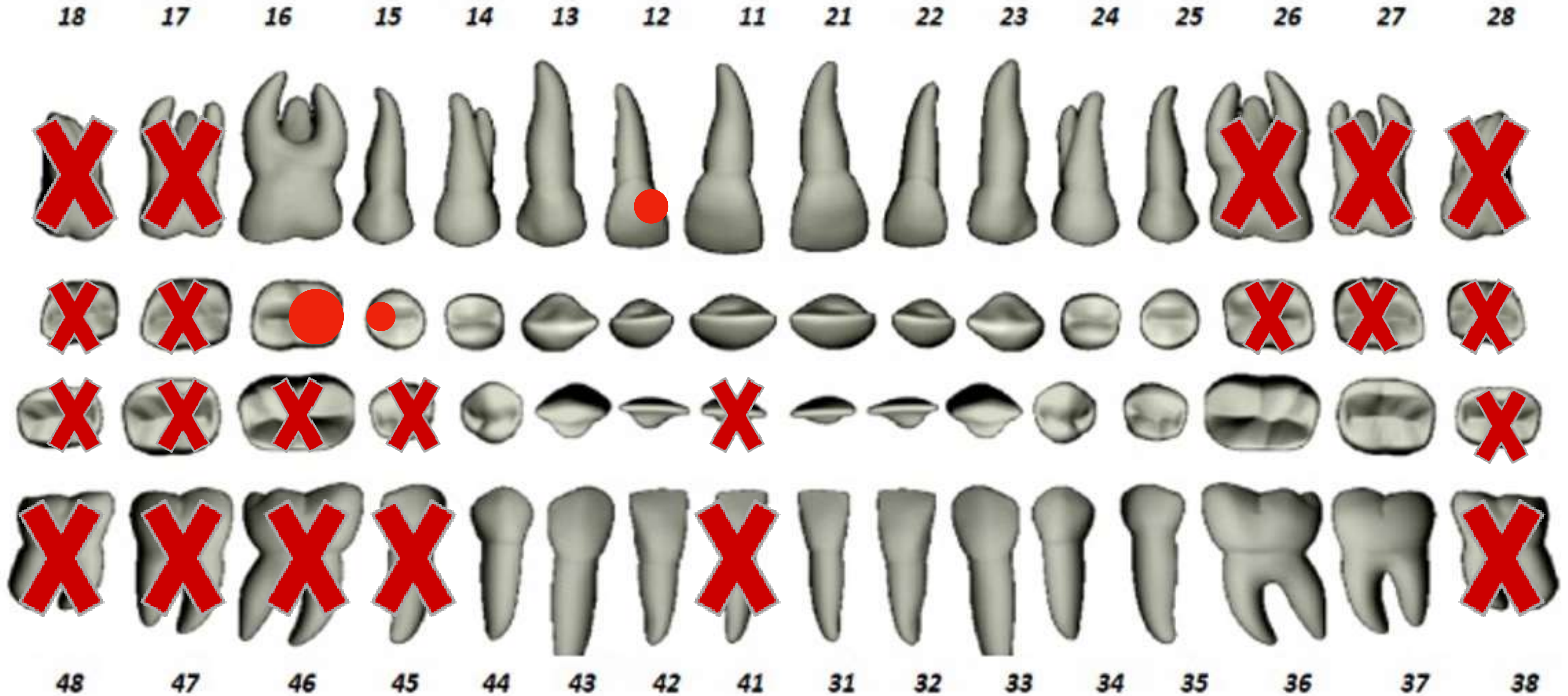


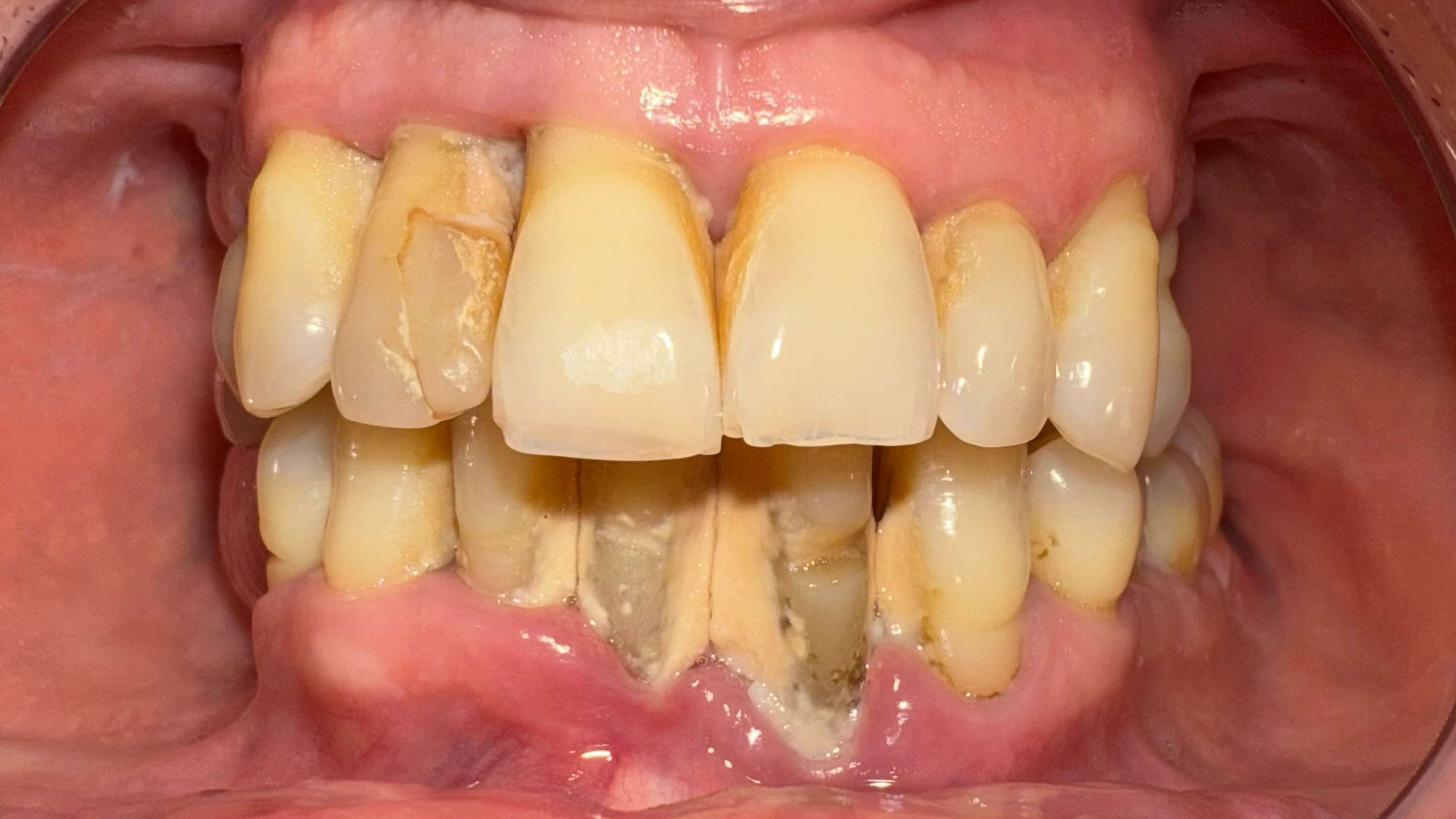PRESENTACIÓN DE CASO CLÍNICO

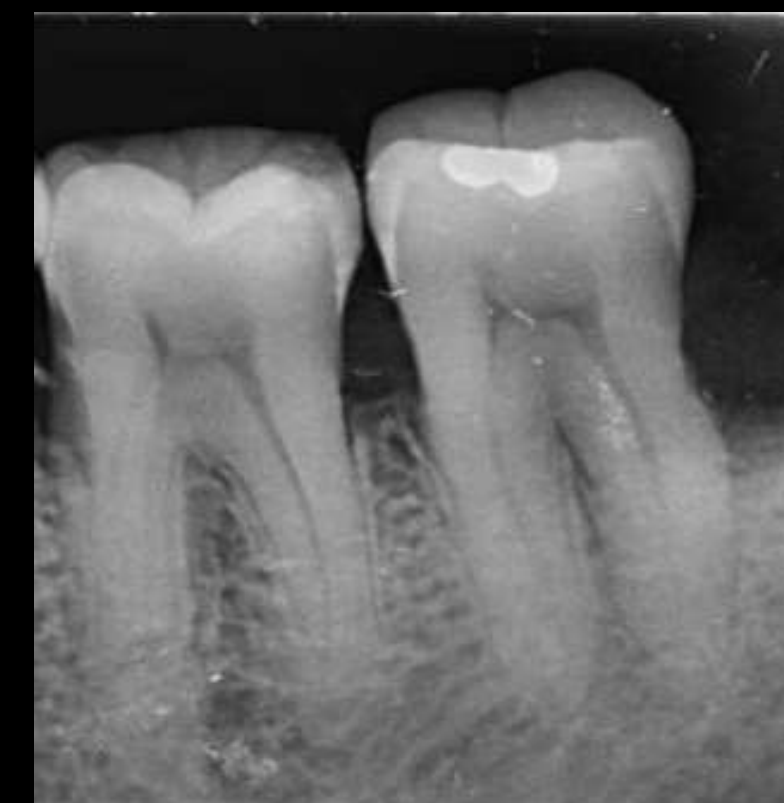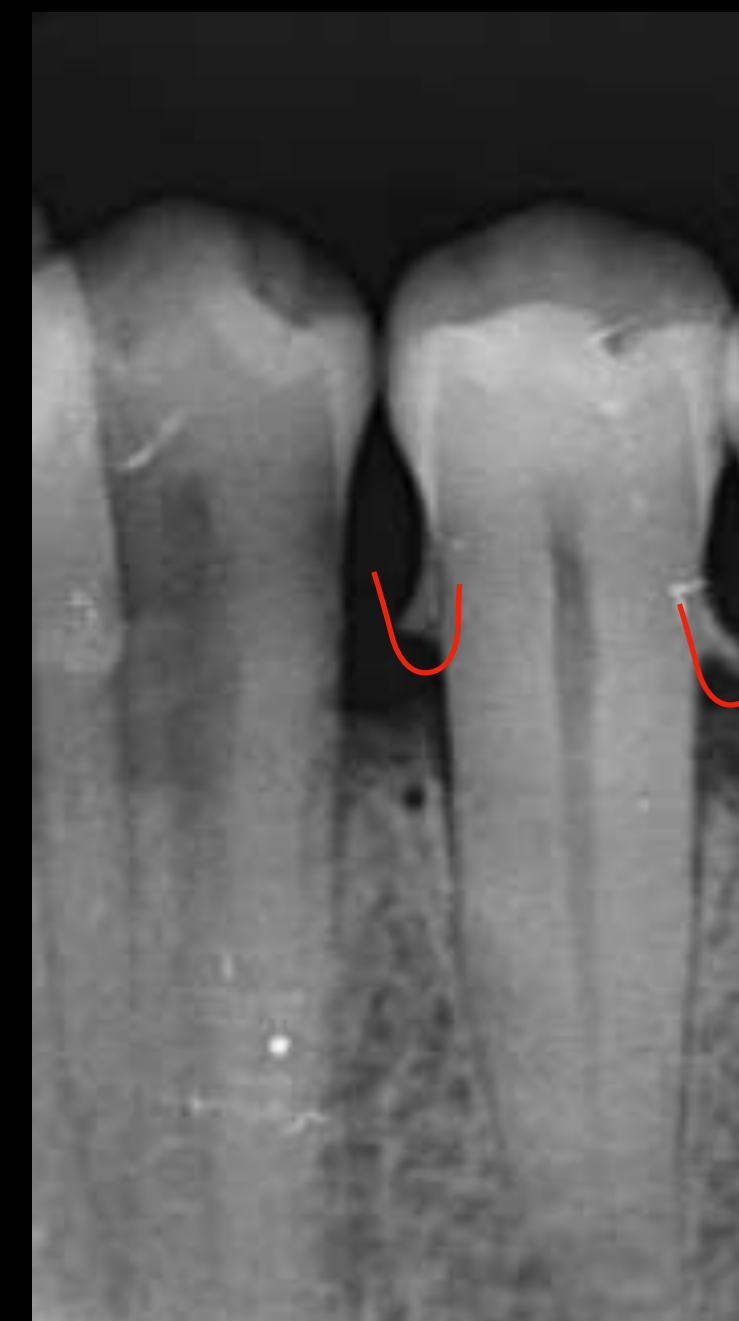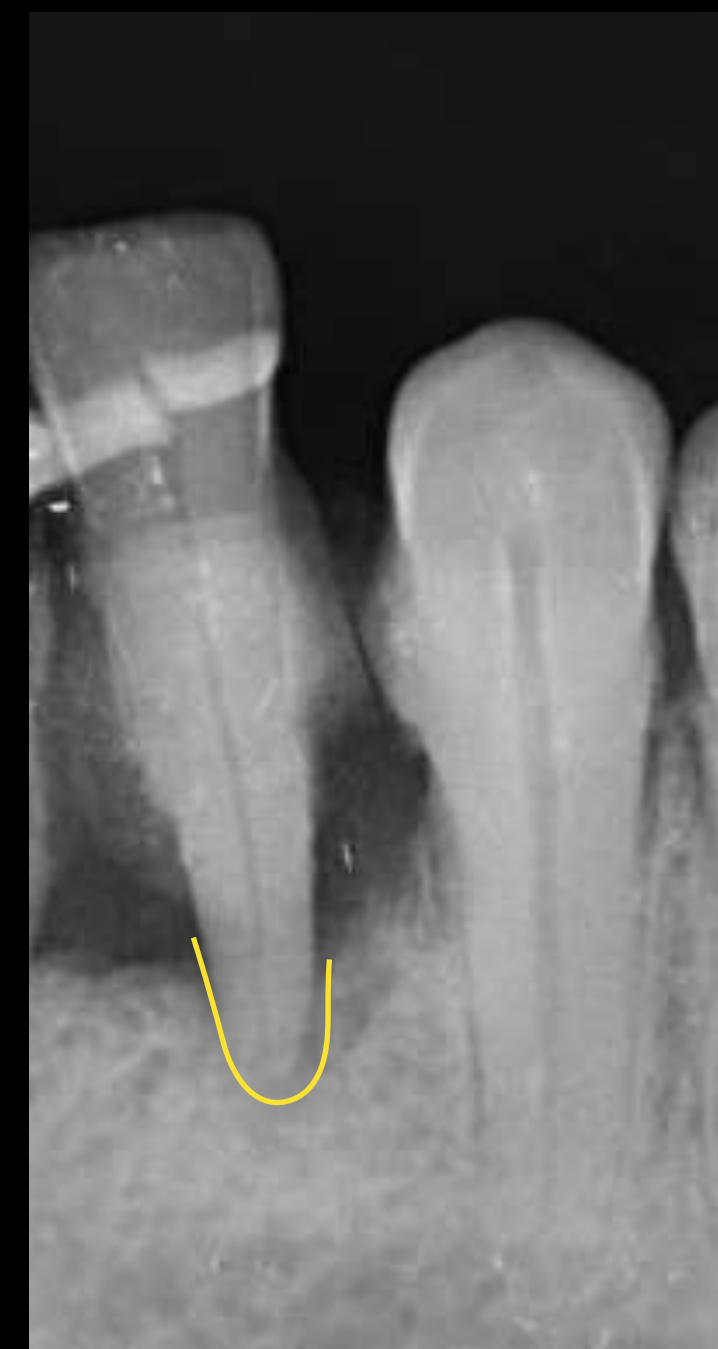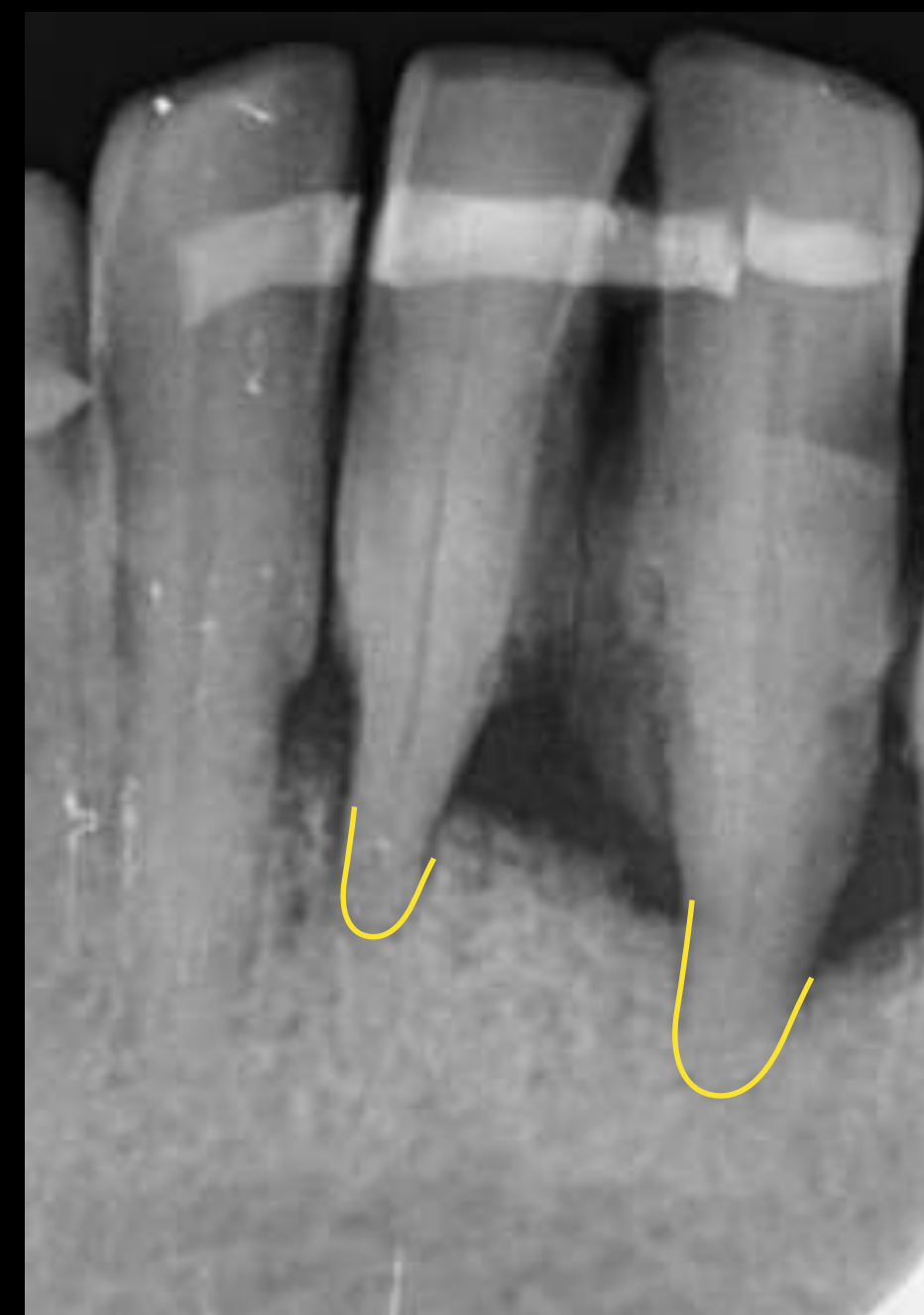
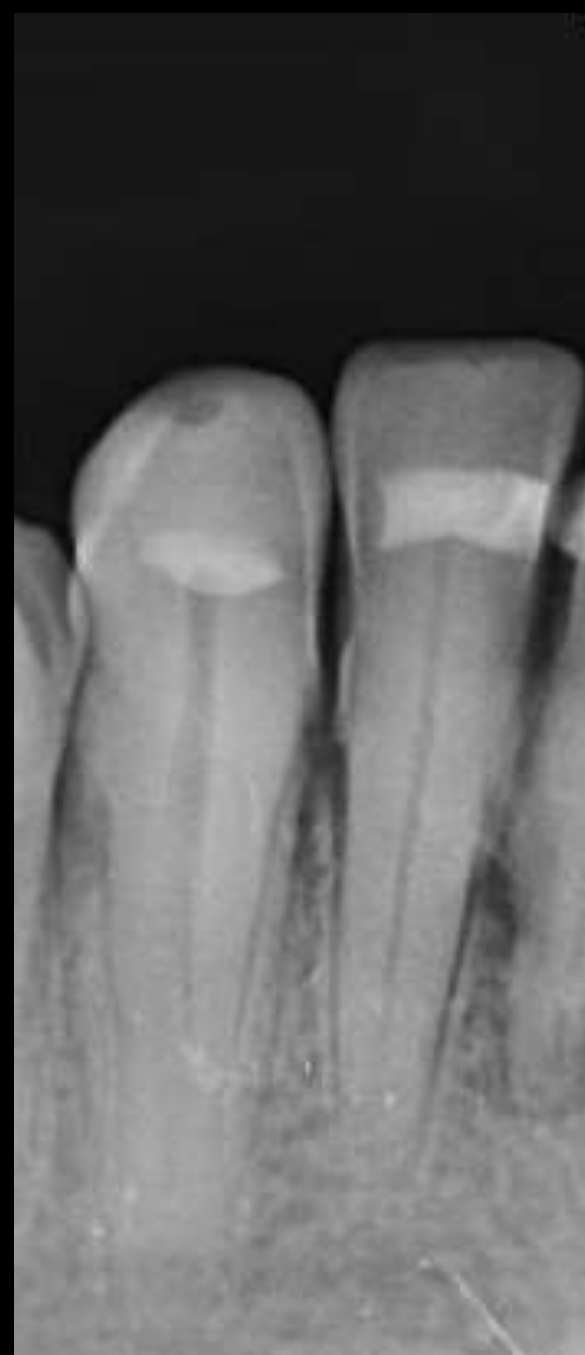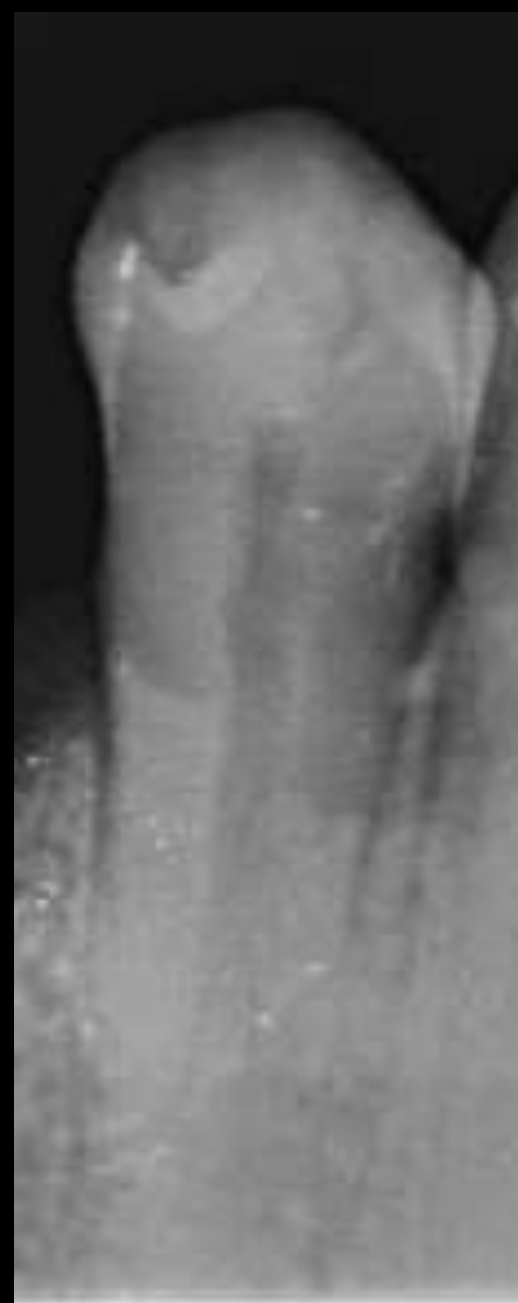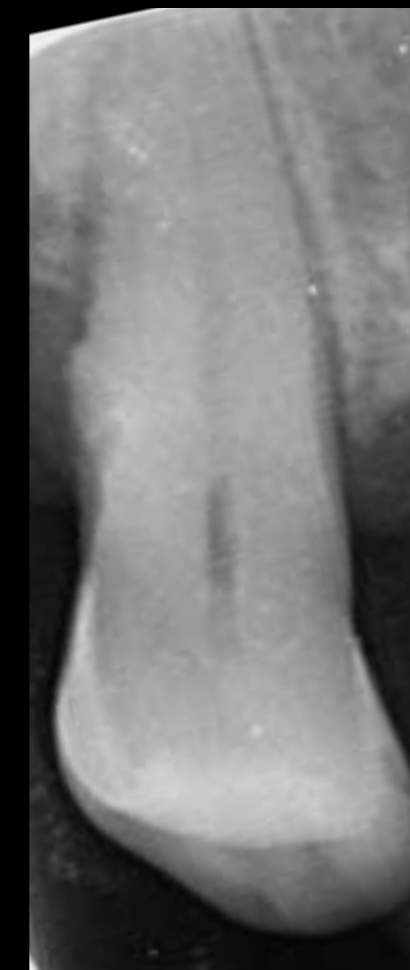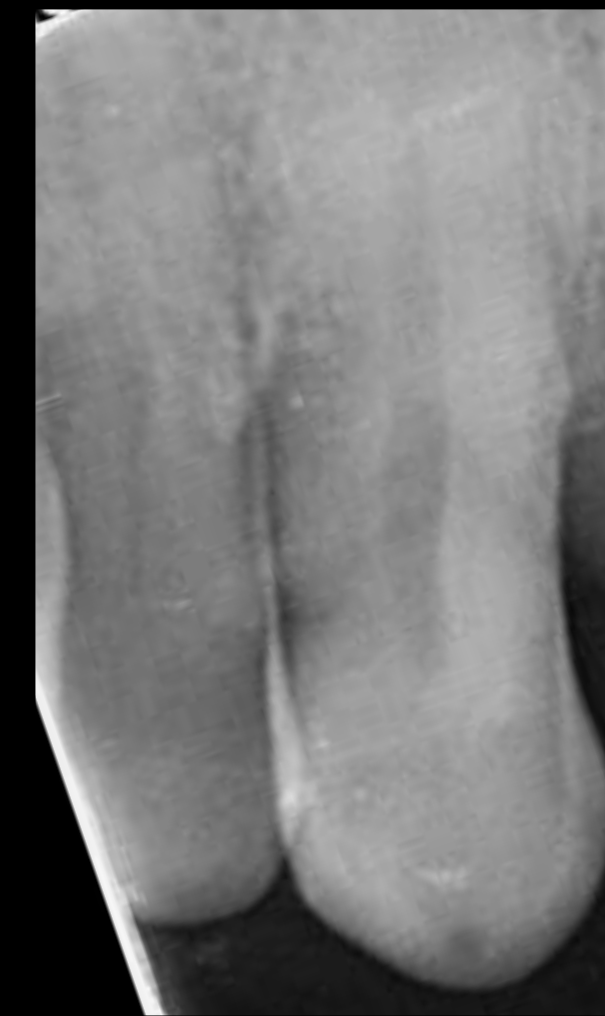
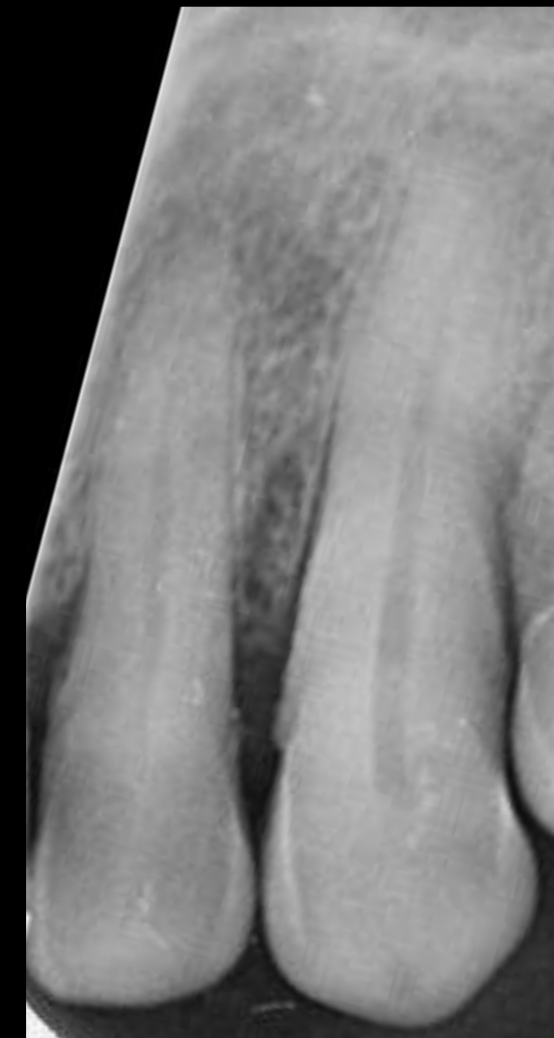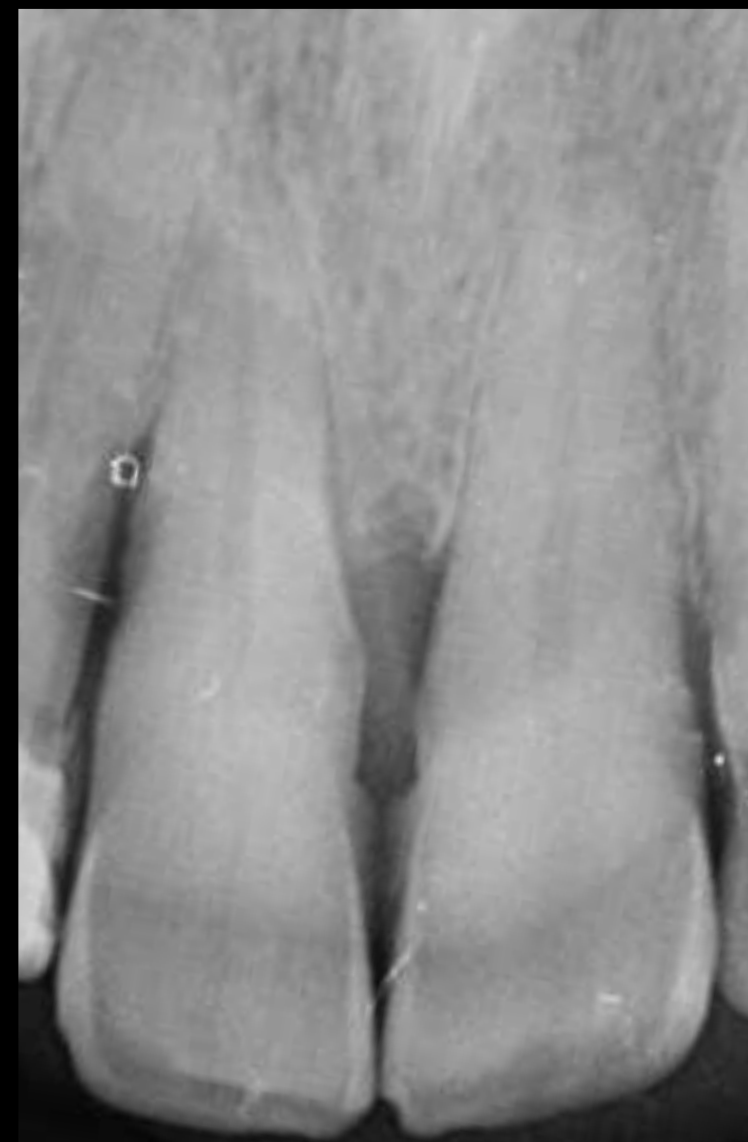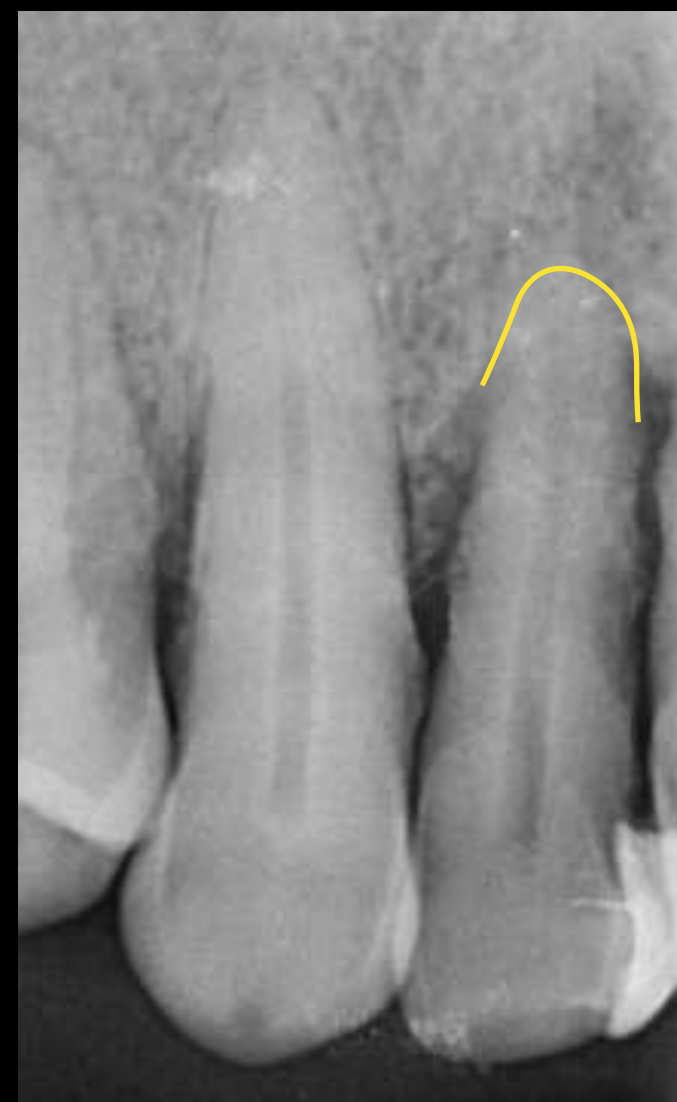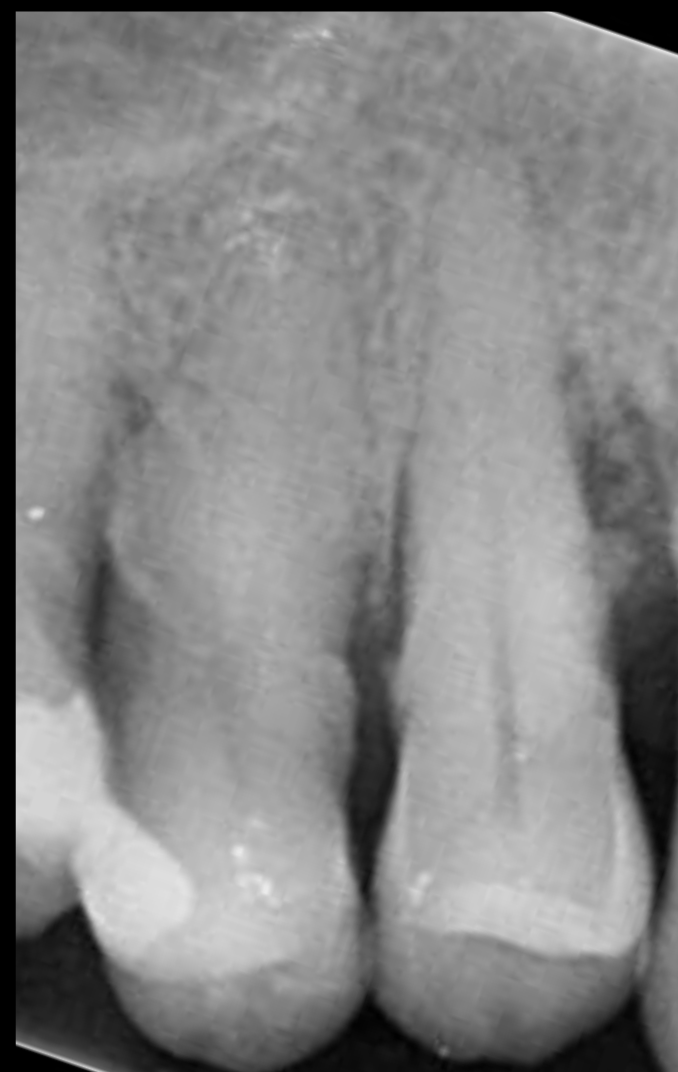
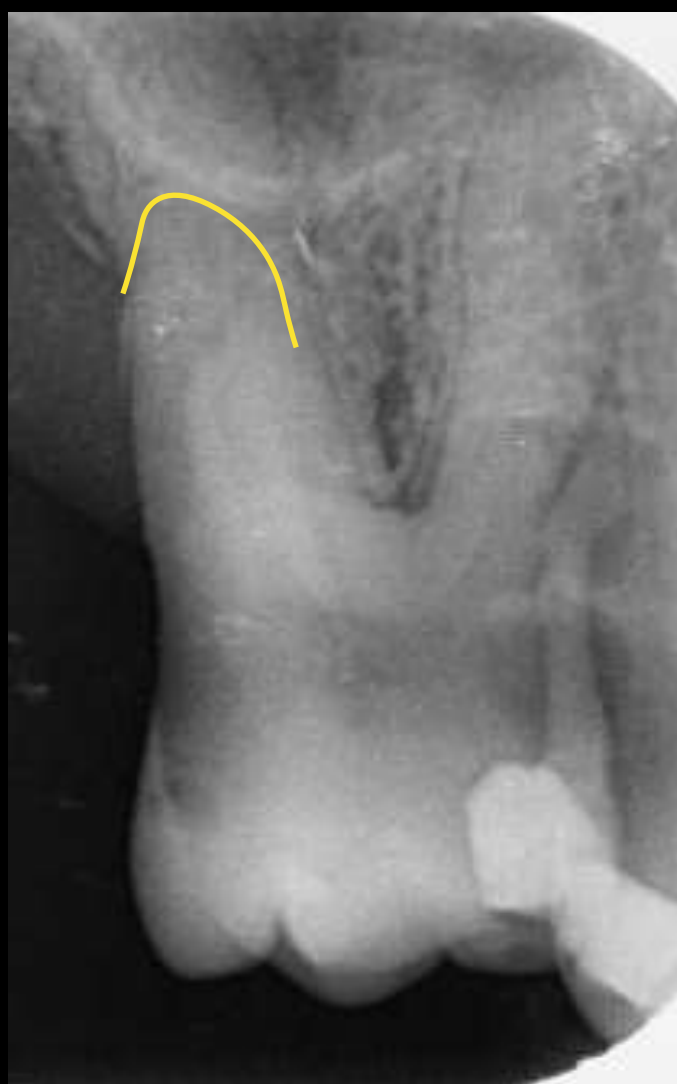Al. Alvarez Alvaro

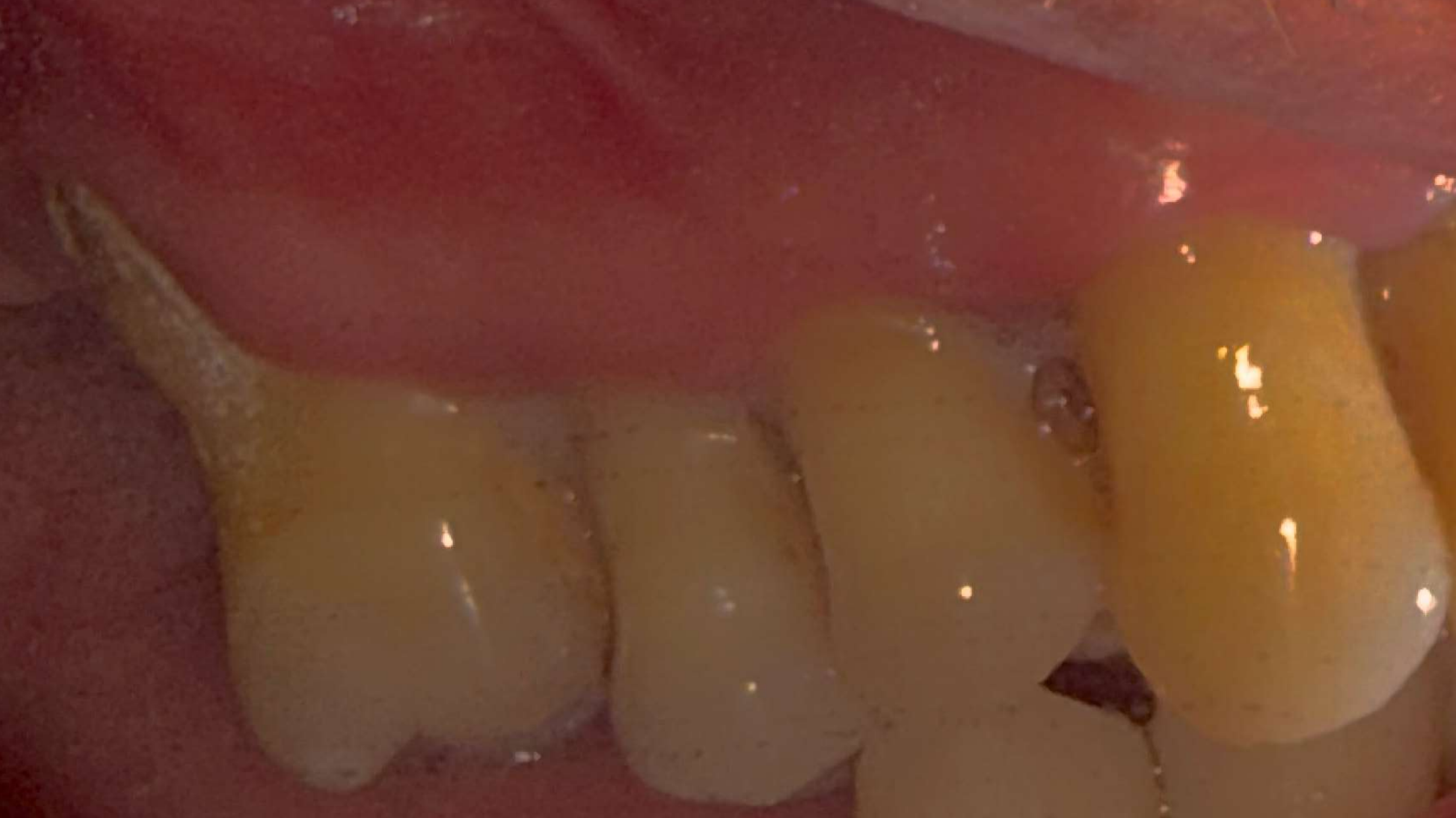Carrera de Odontología
Universidad Católica de La Plata
Cátedra Periodoncia II 2025

EXAMEN DENTAL

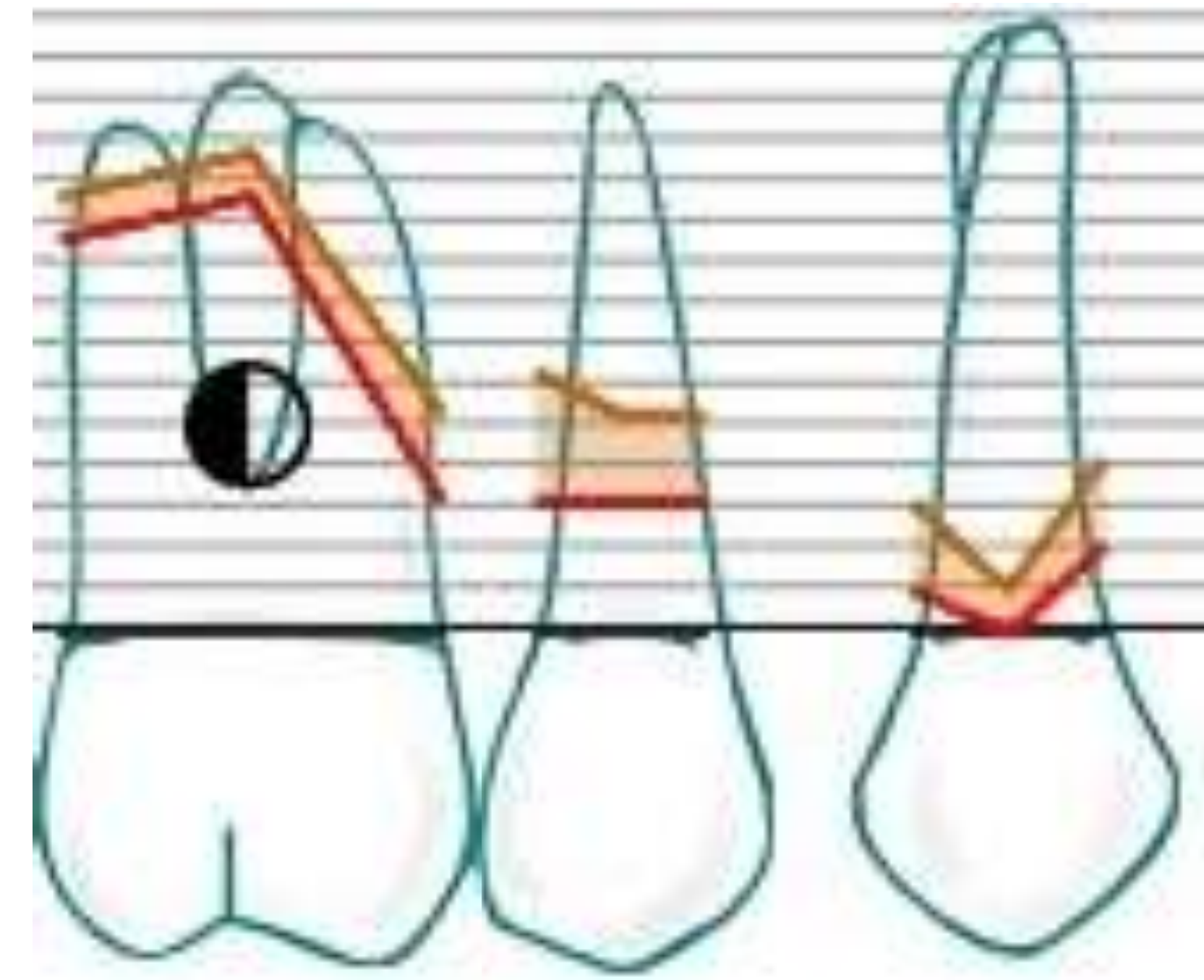
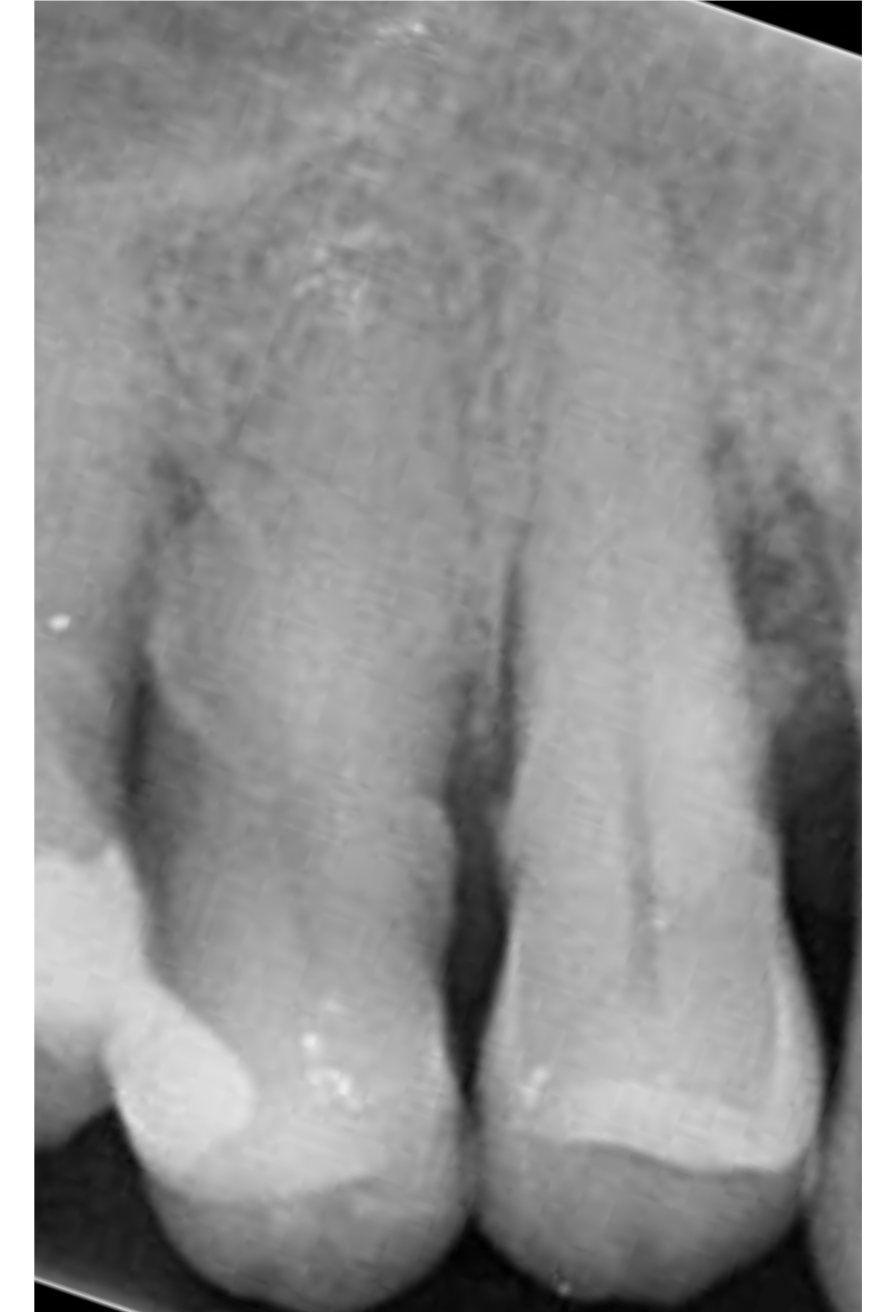
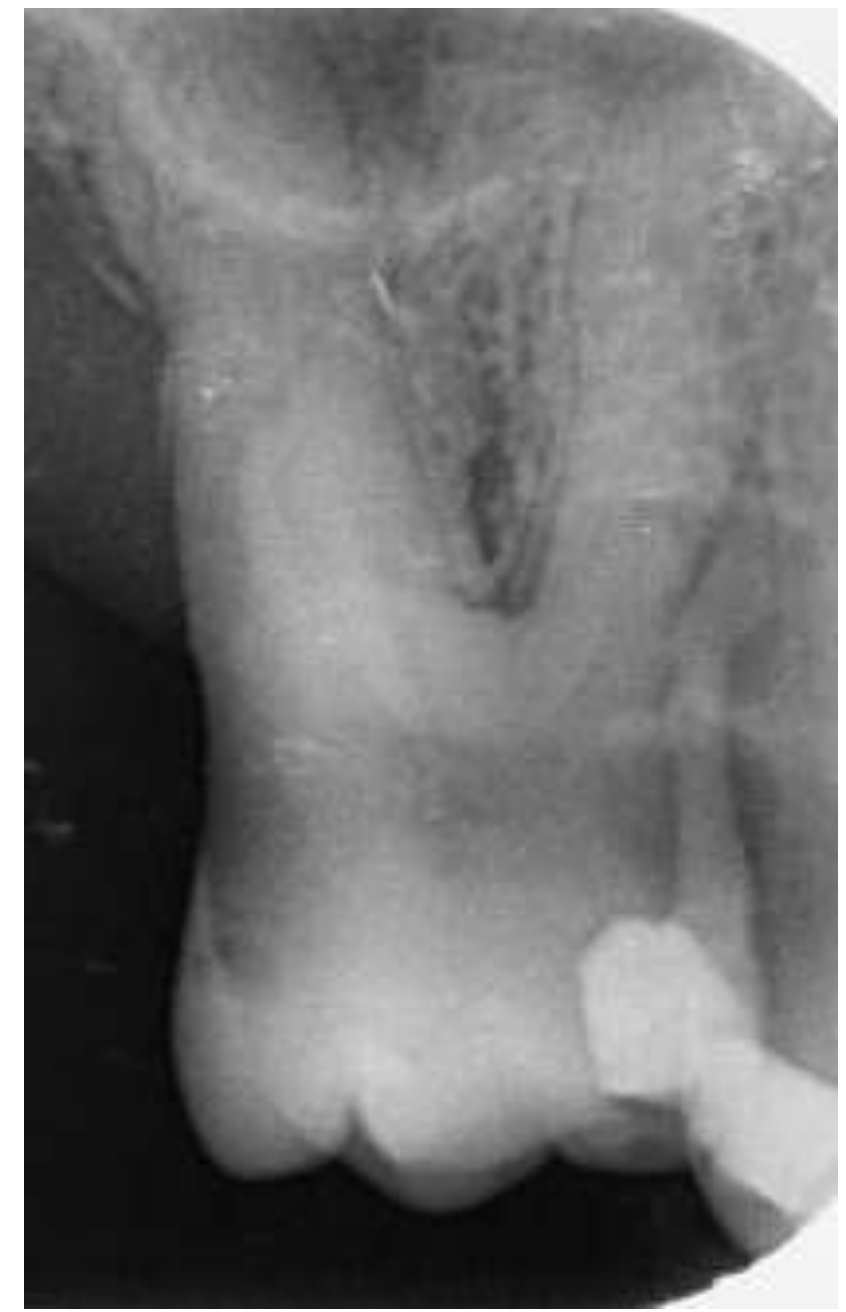




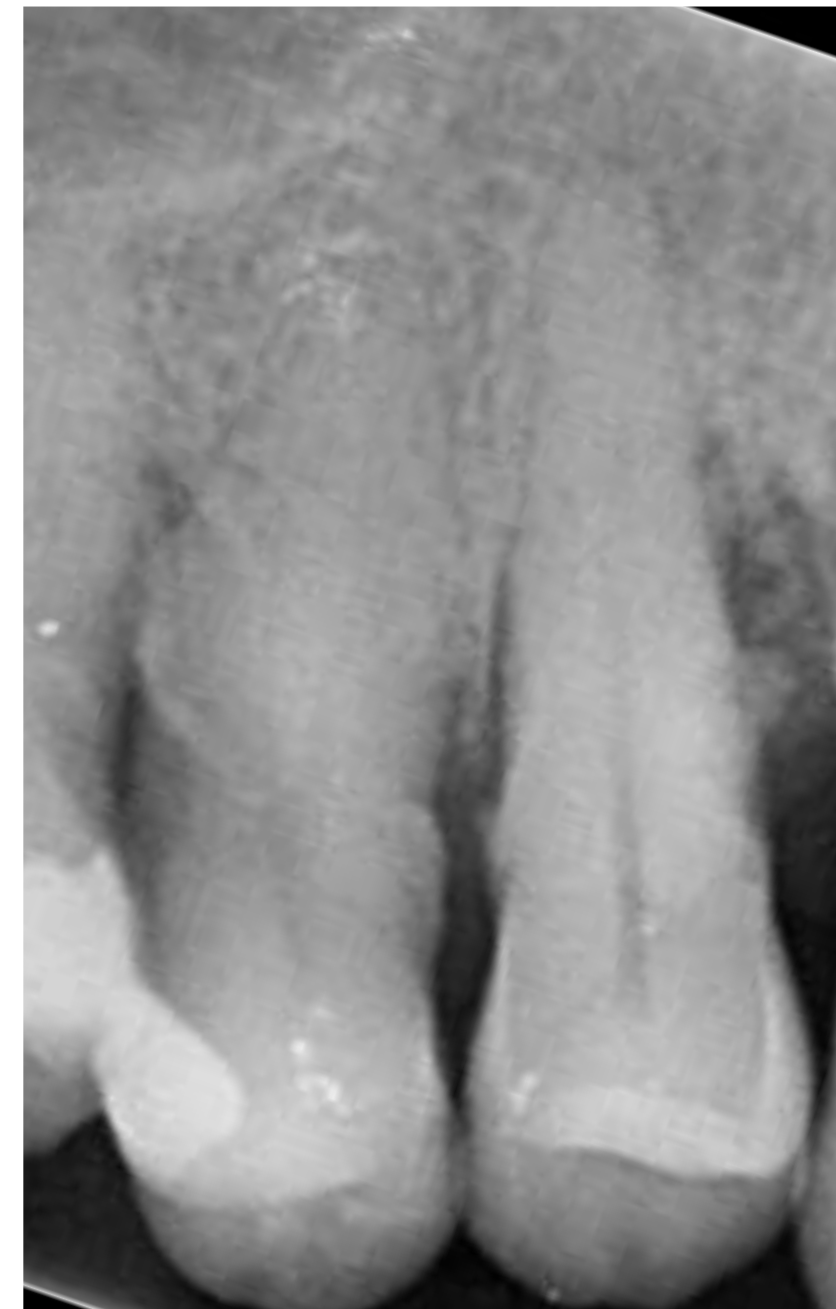
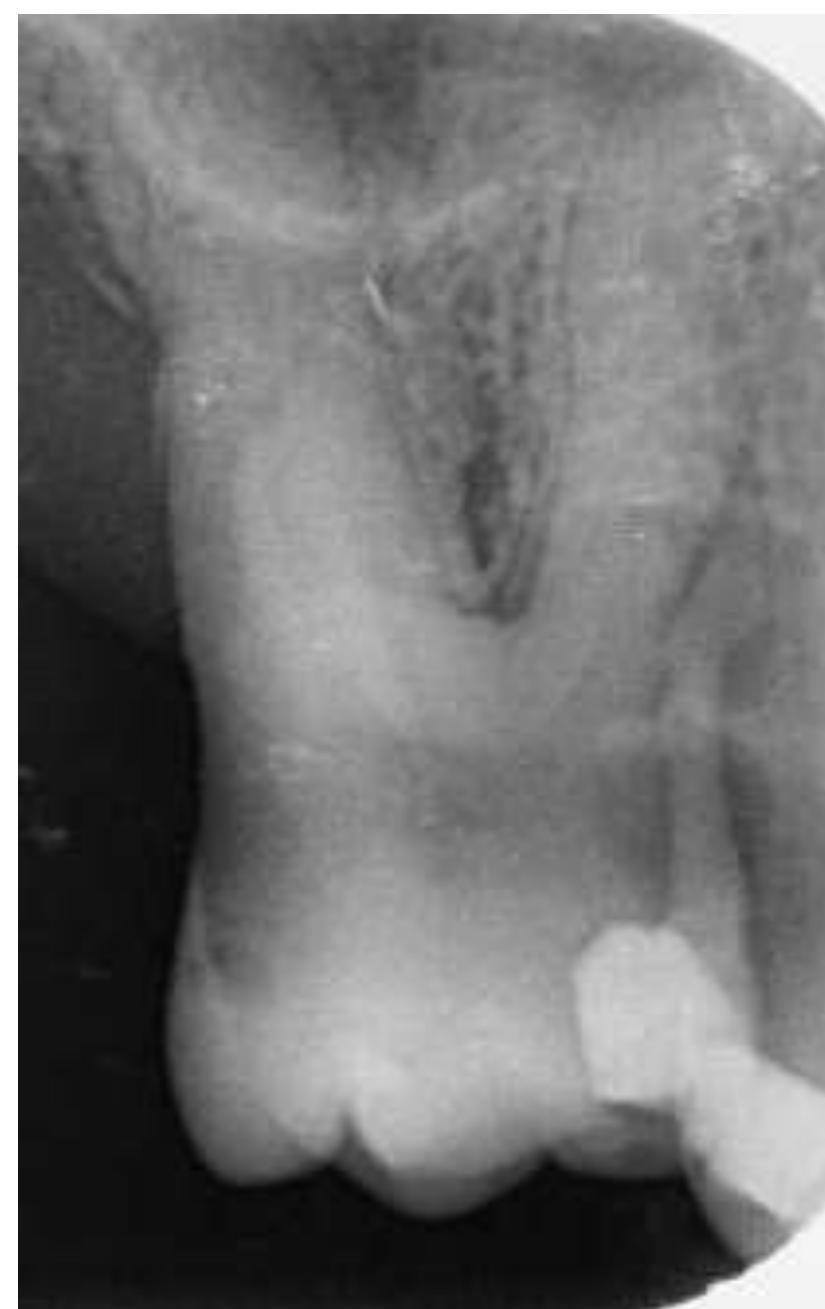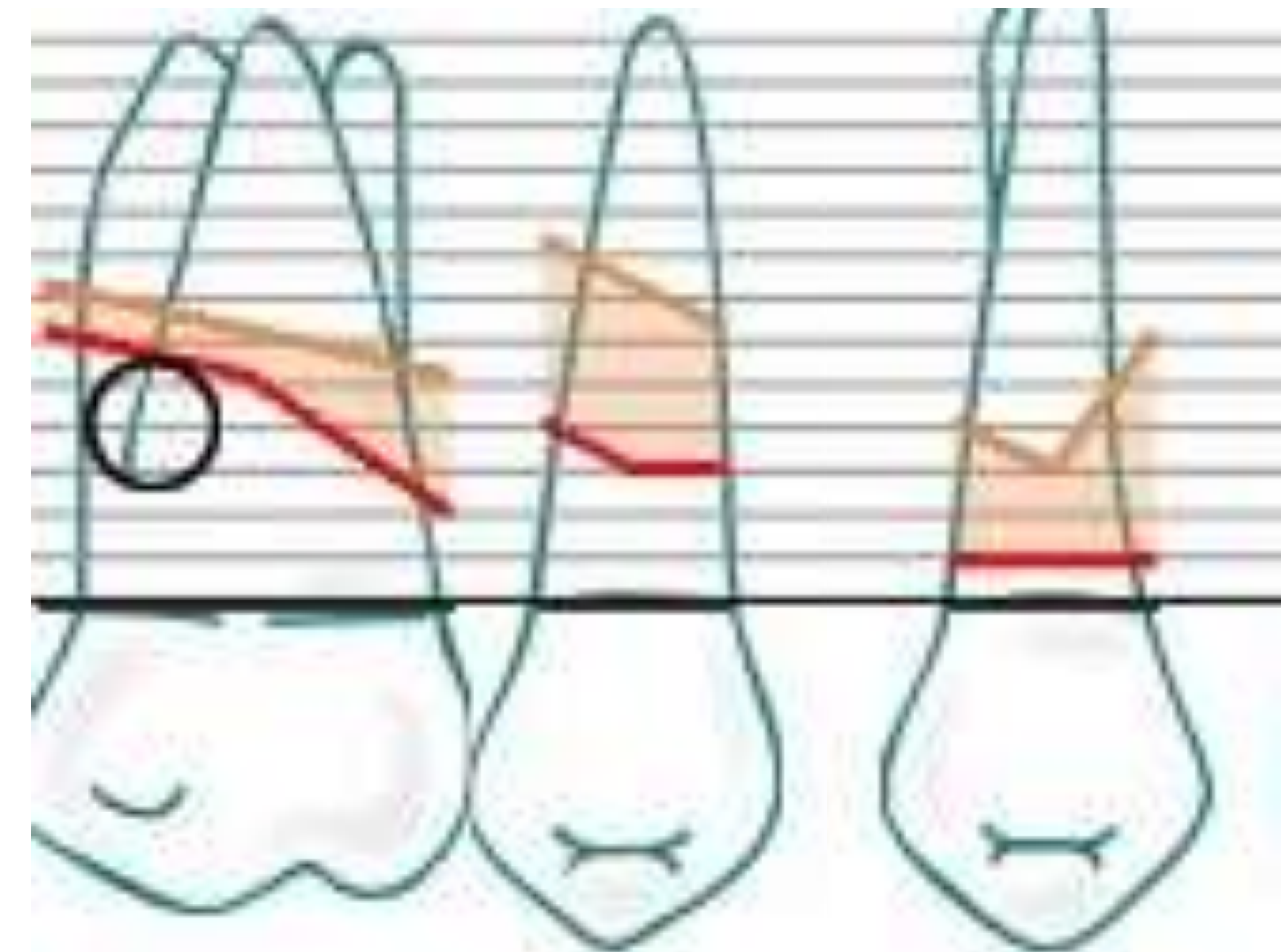


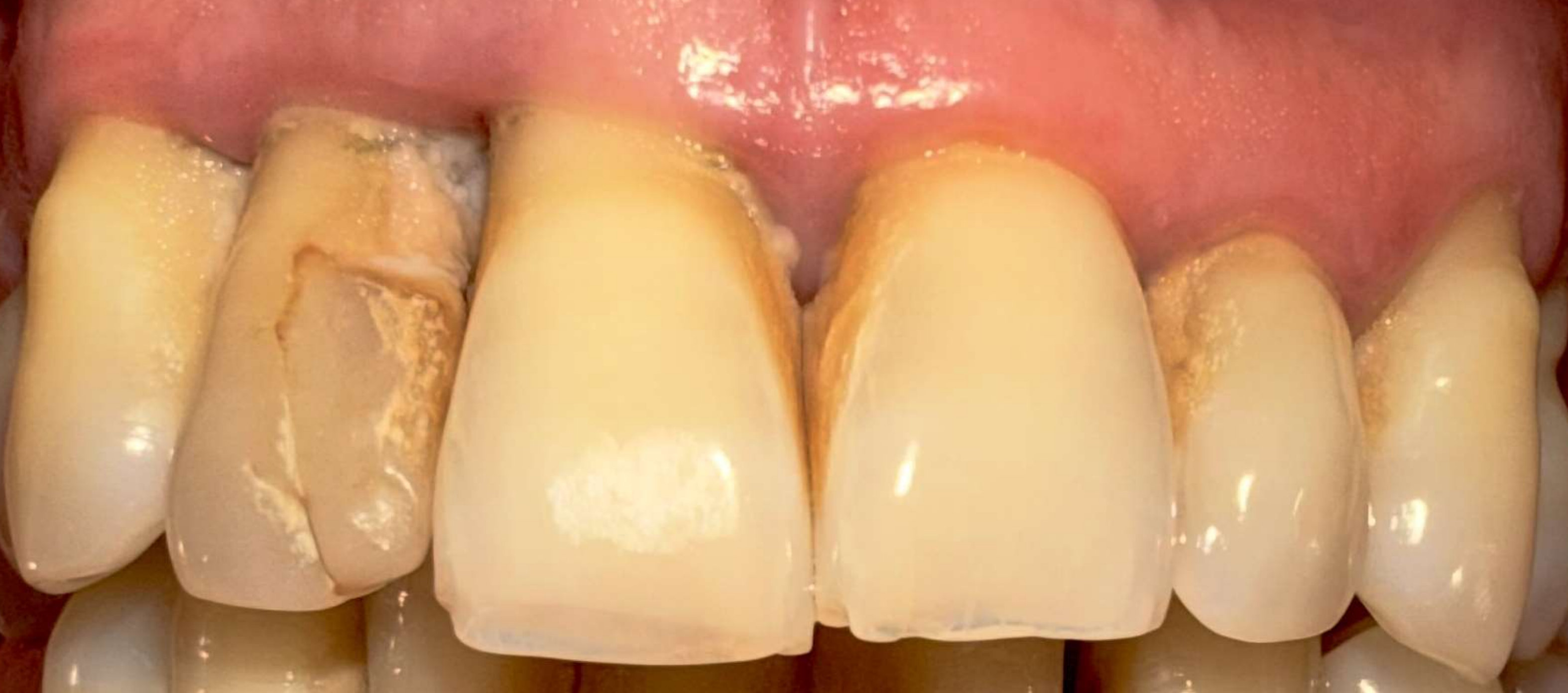10	11	5	6	5	5	3	1	4
1	1	2	3	2	2	2	1	2



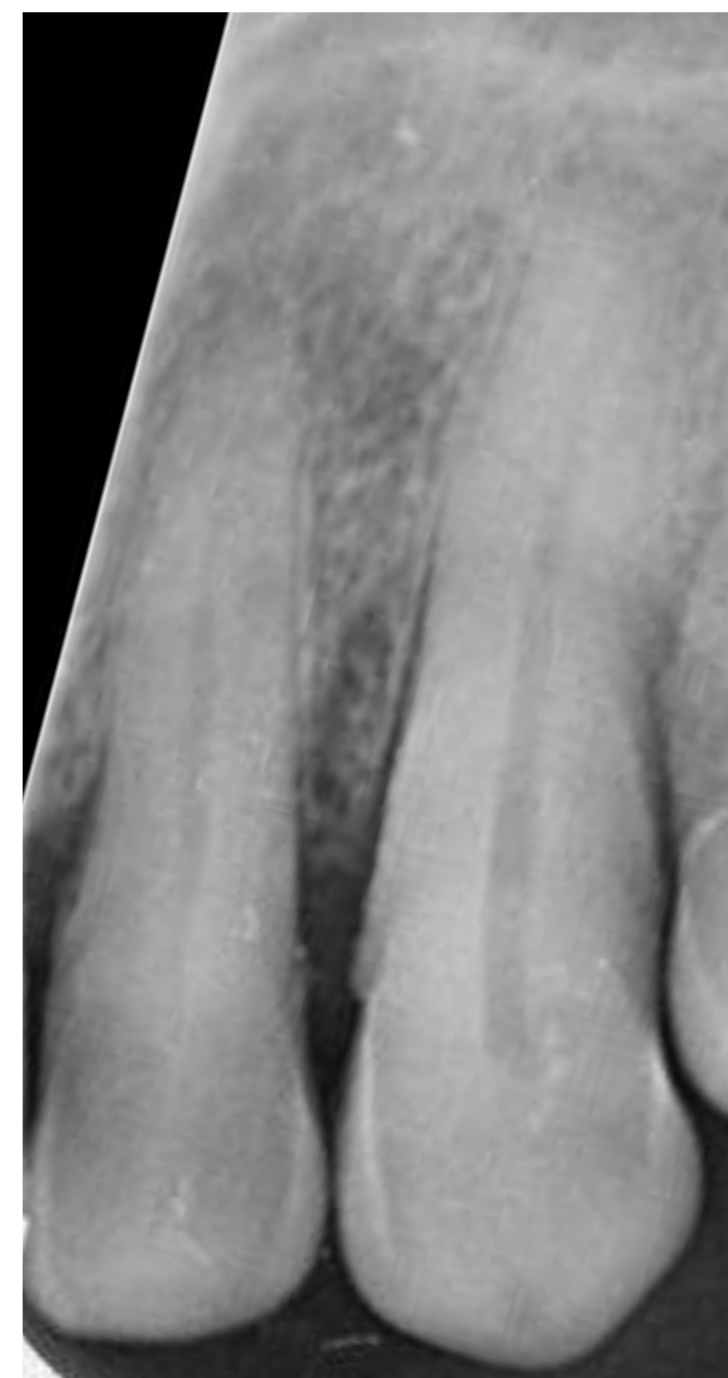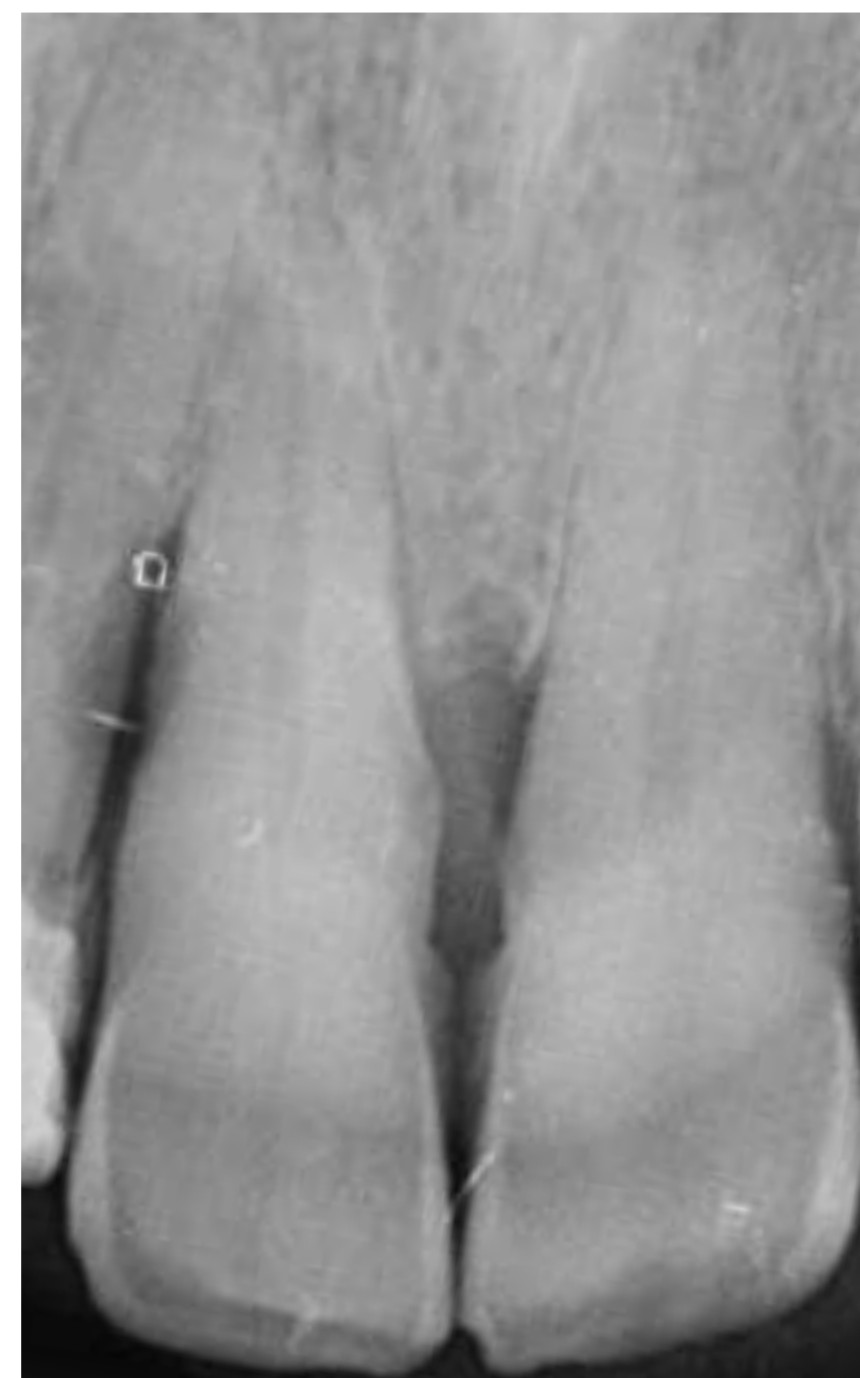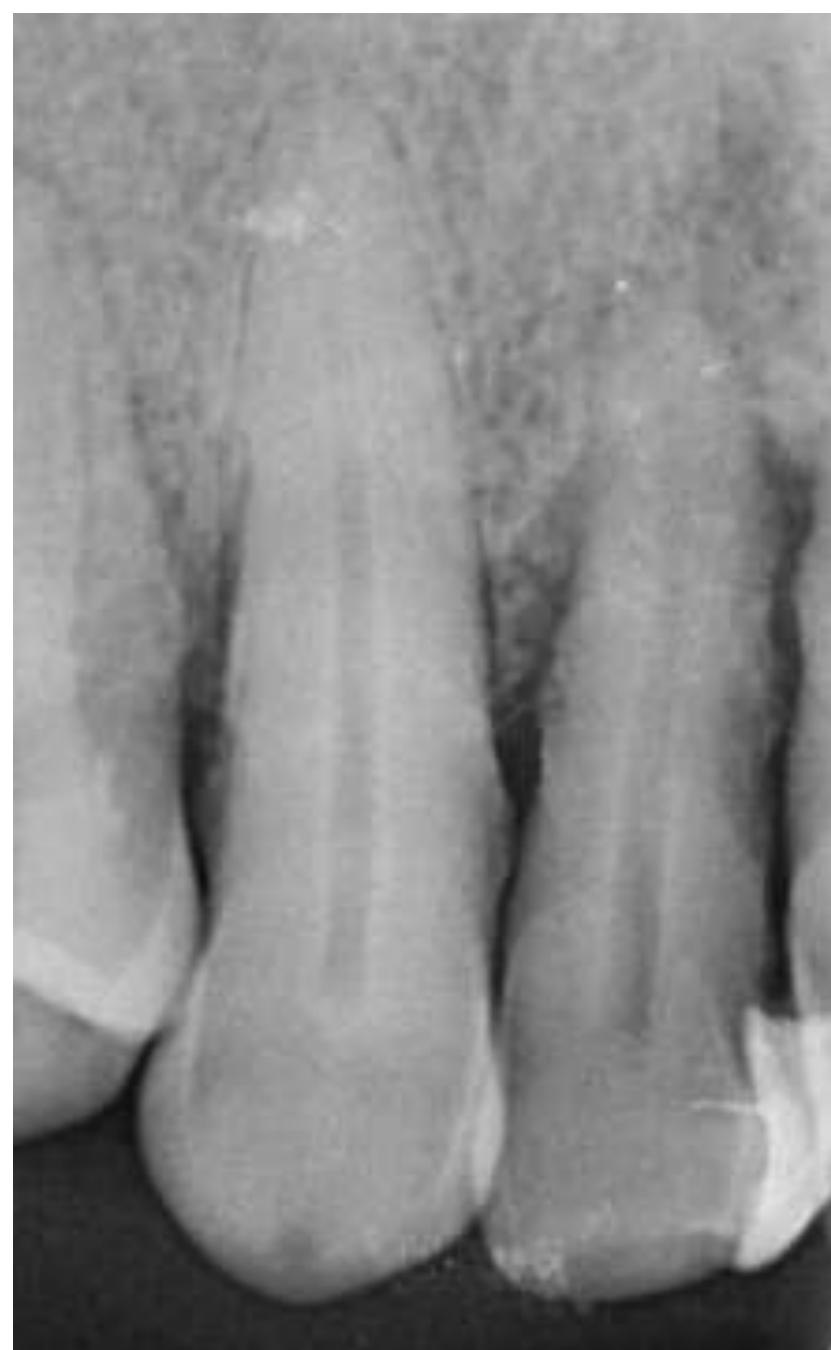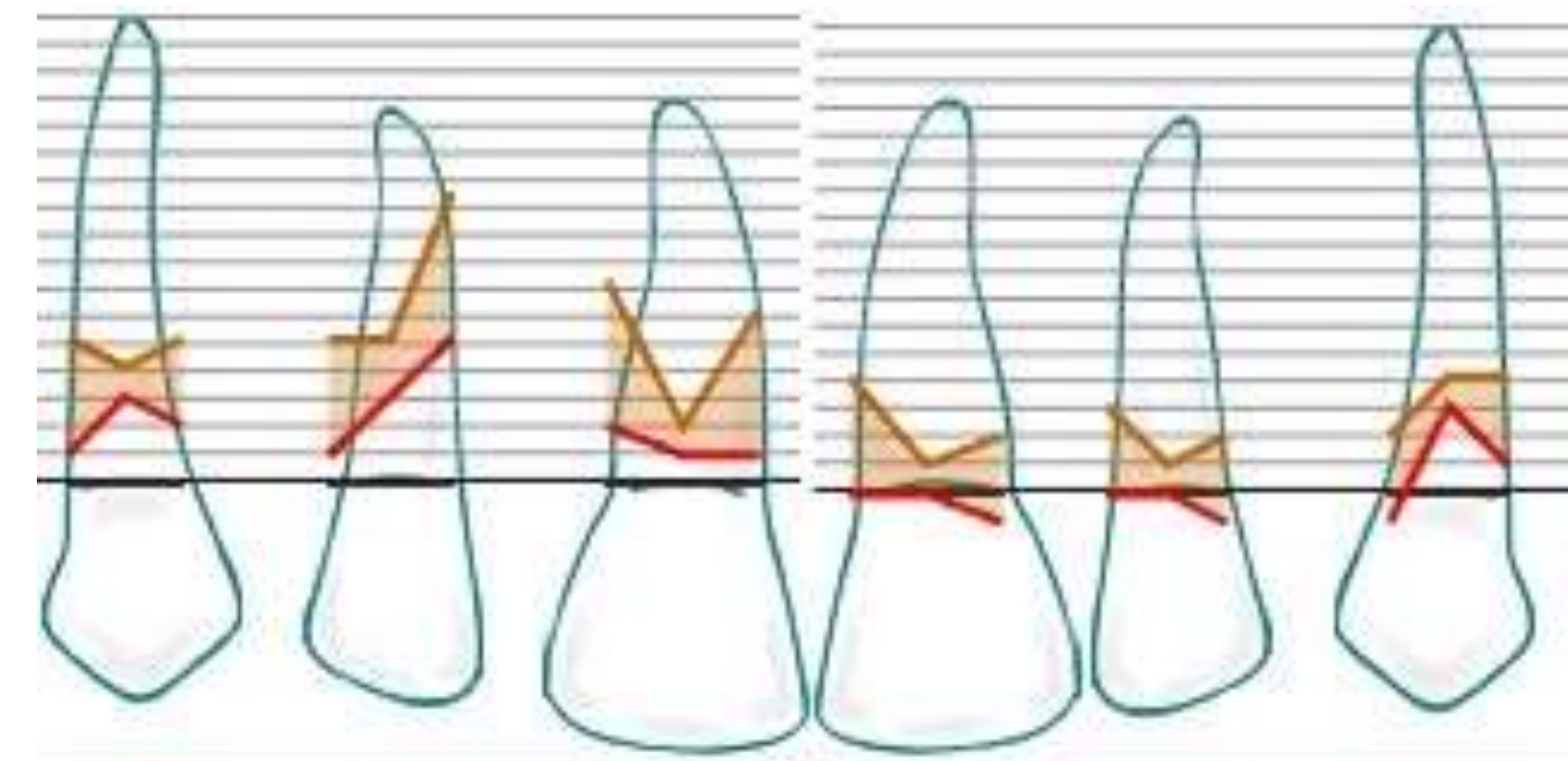


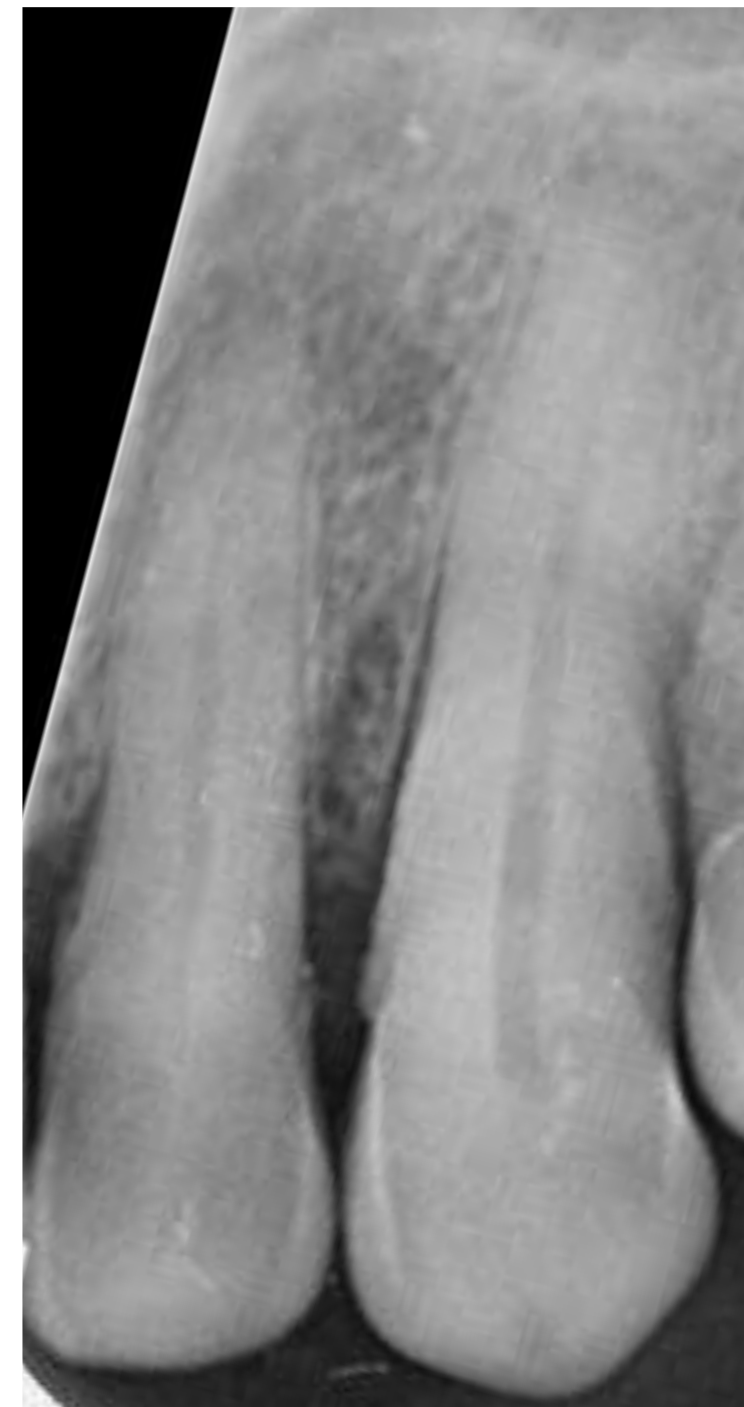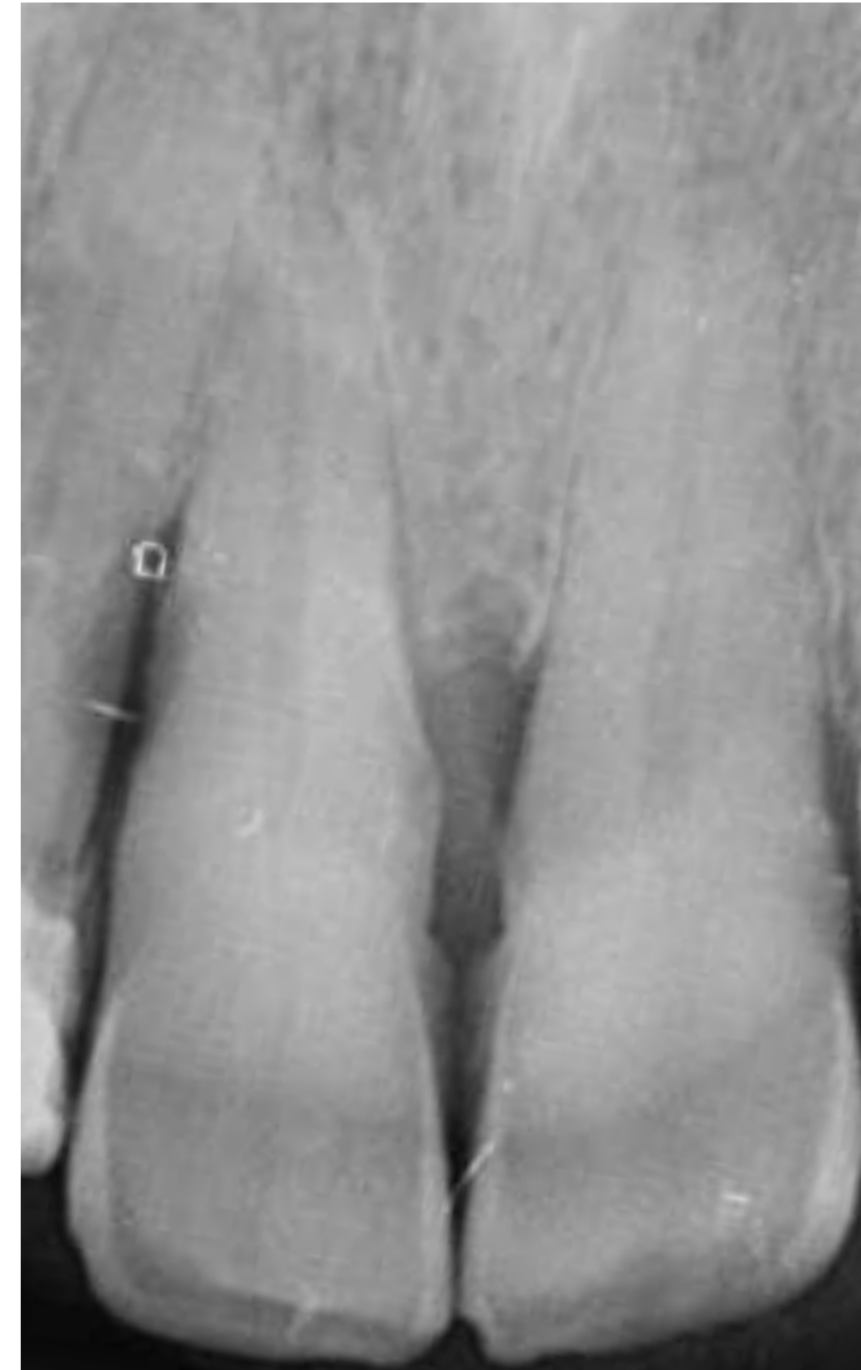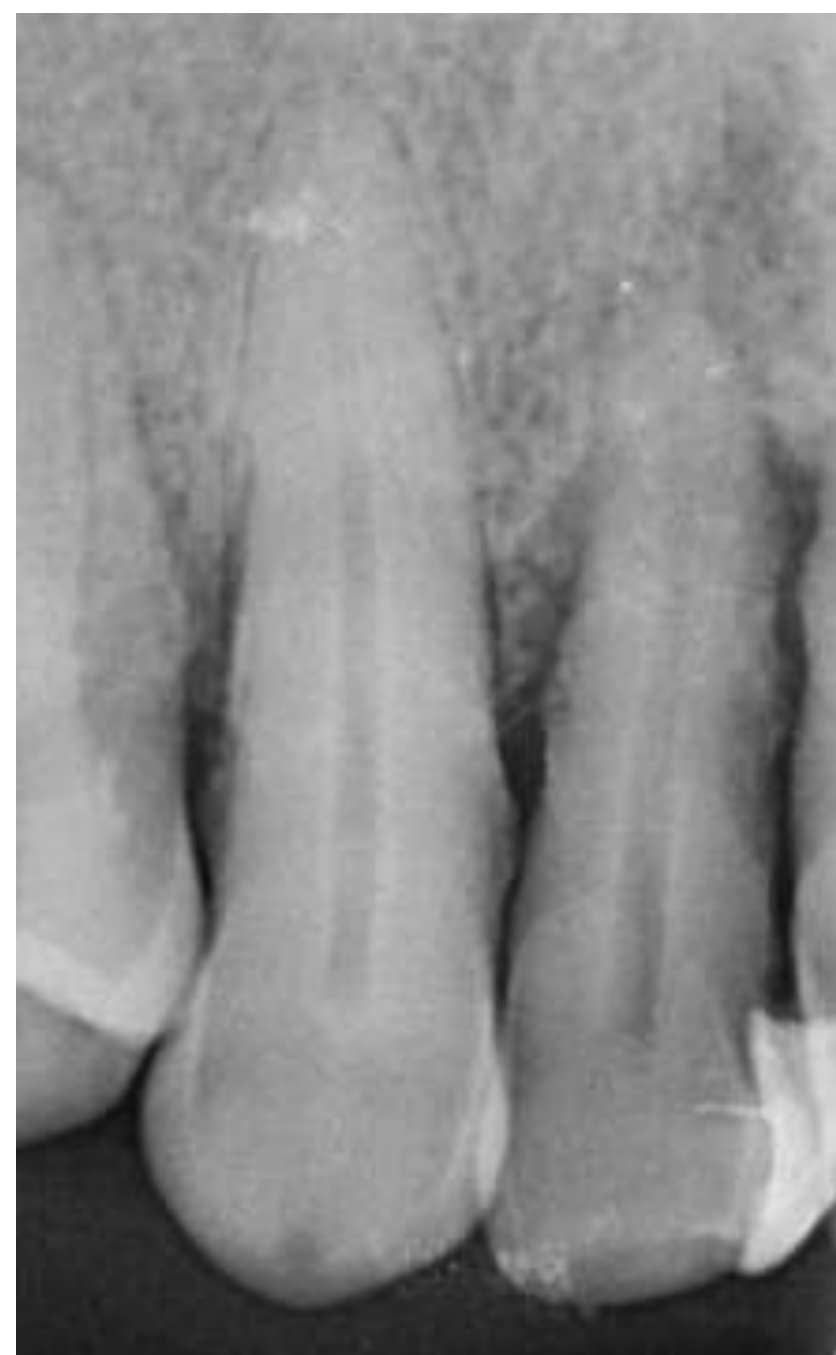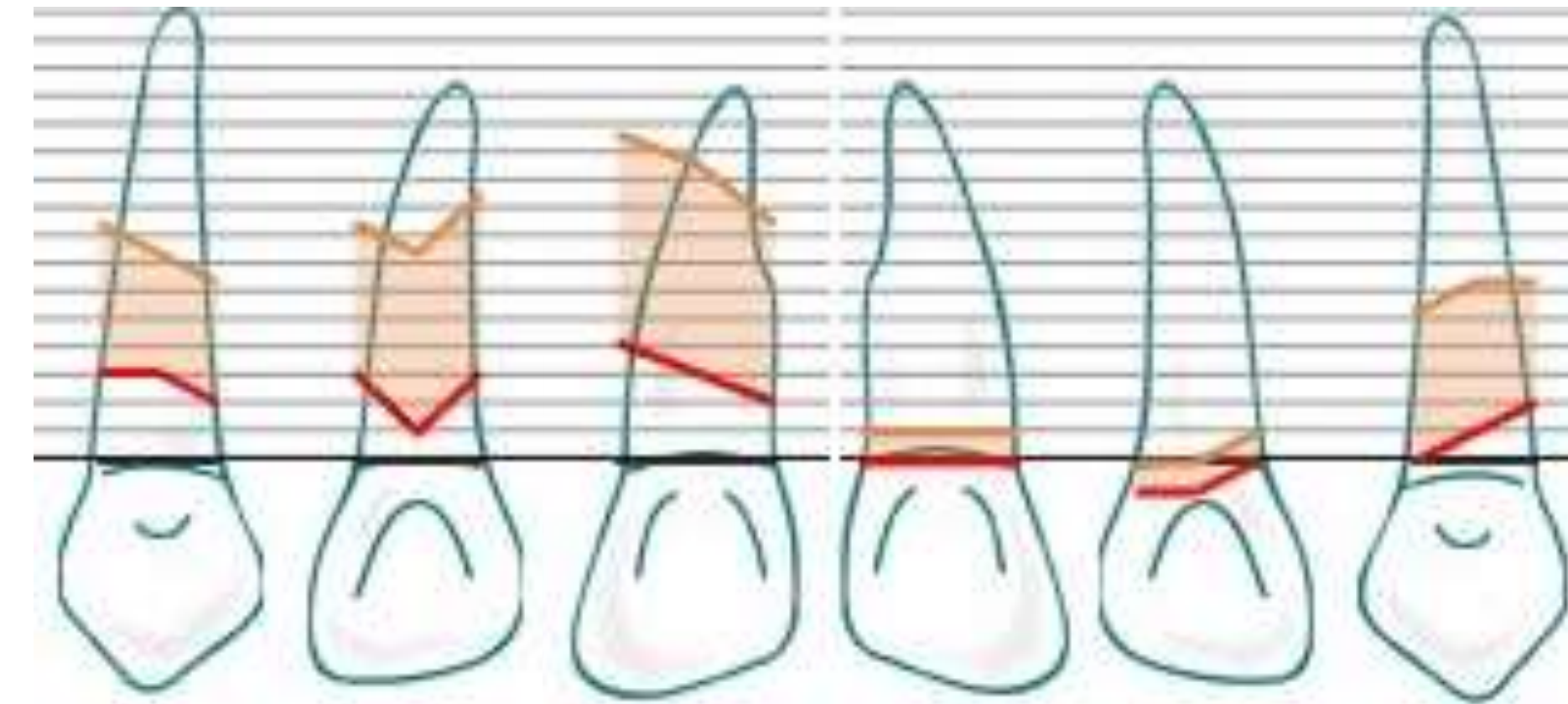
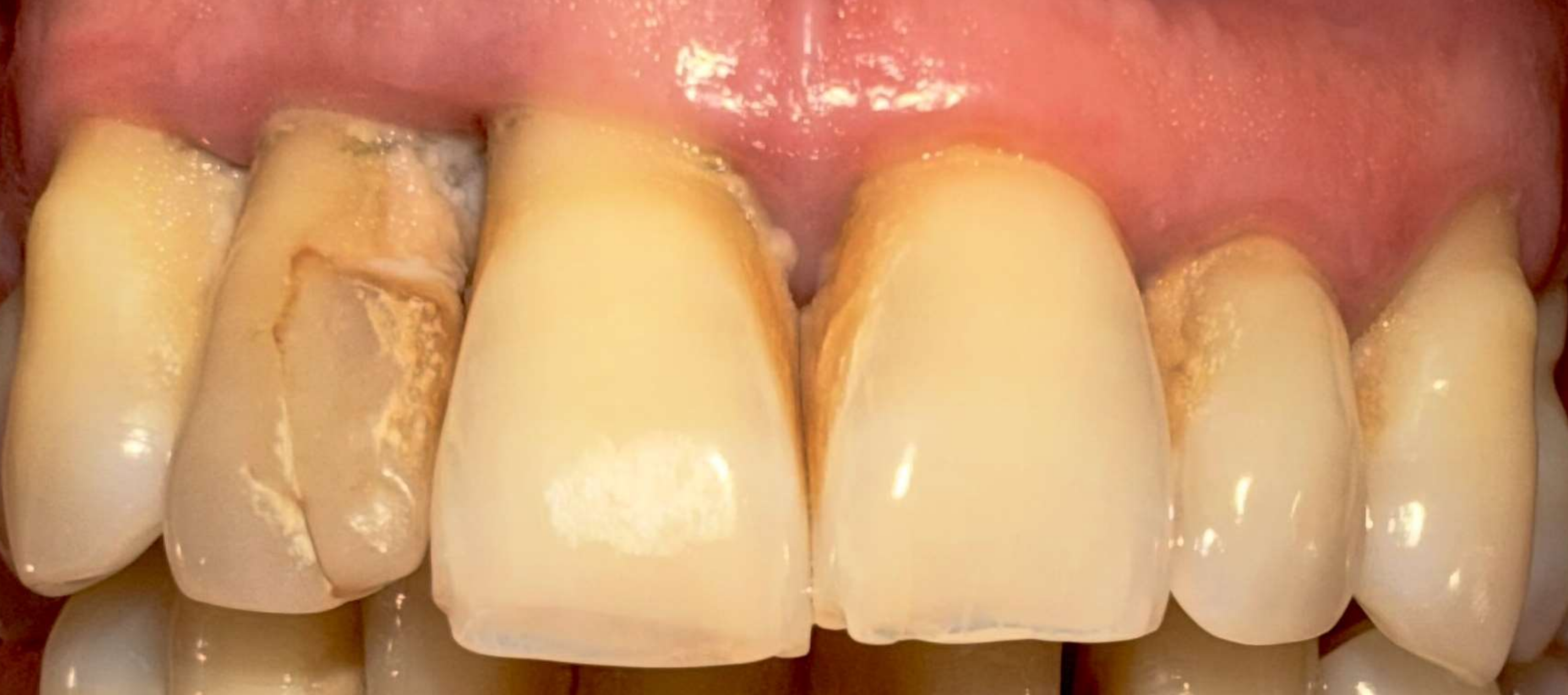1	1	3	4	4	3	3	2	5
7	6	5	8	7	6	4	3	6



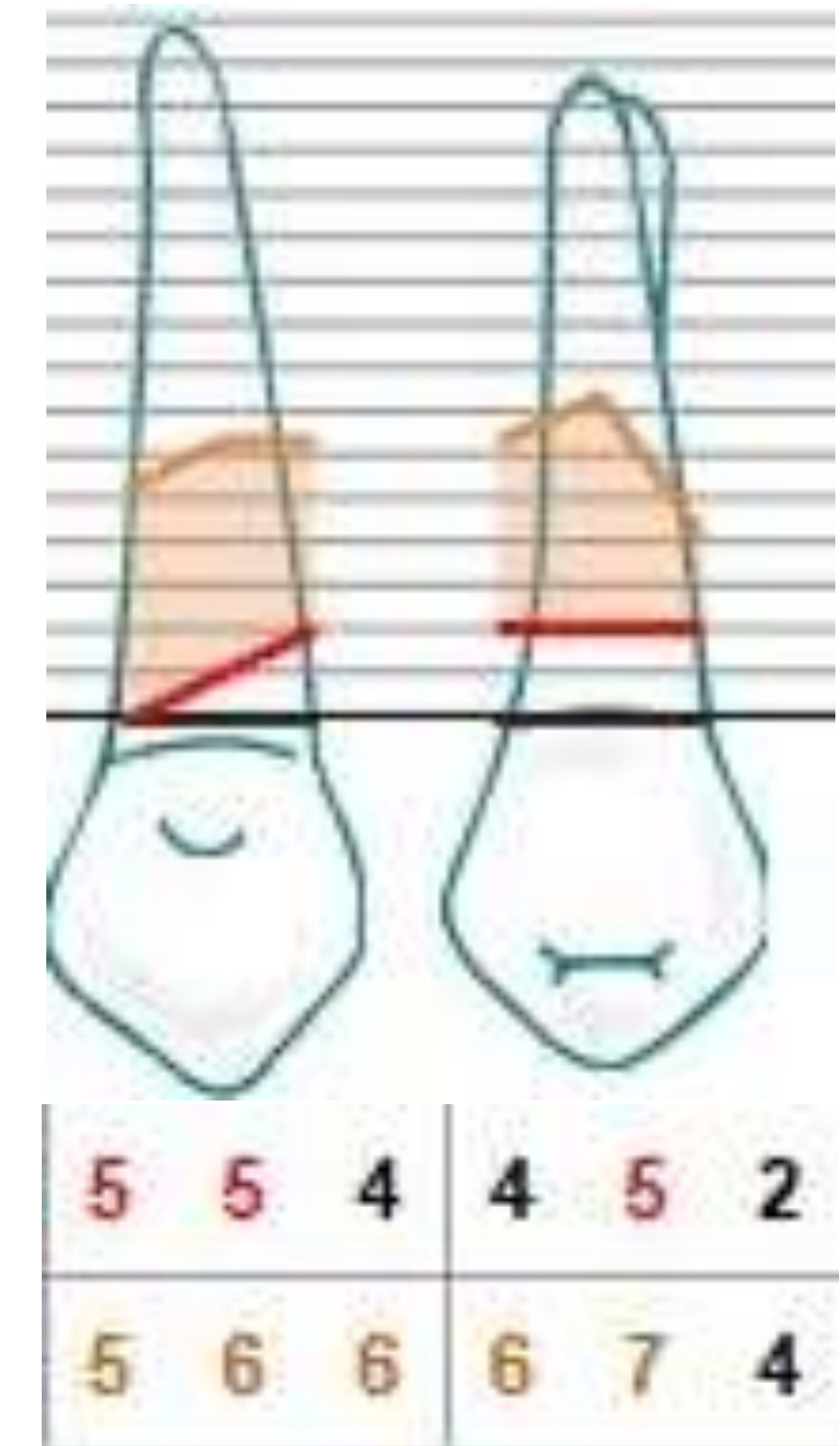
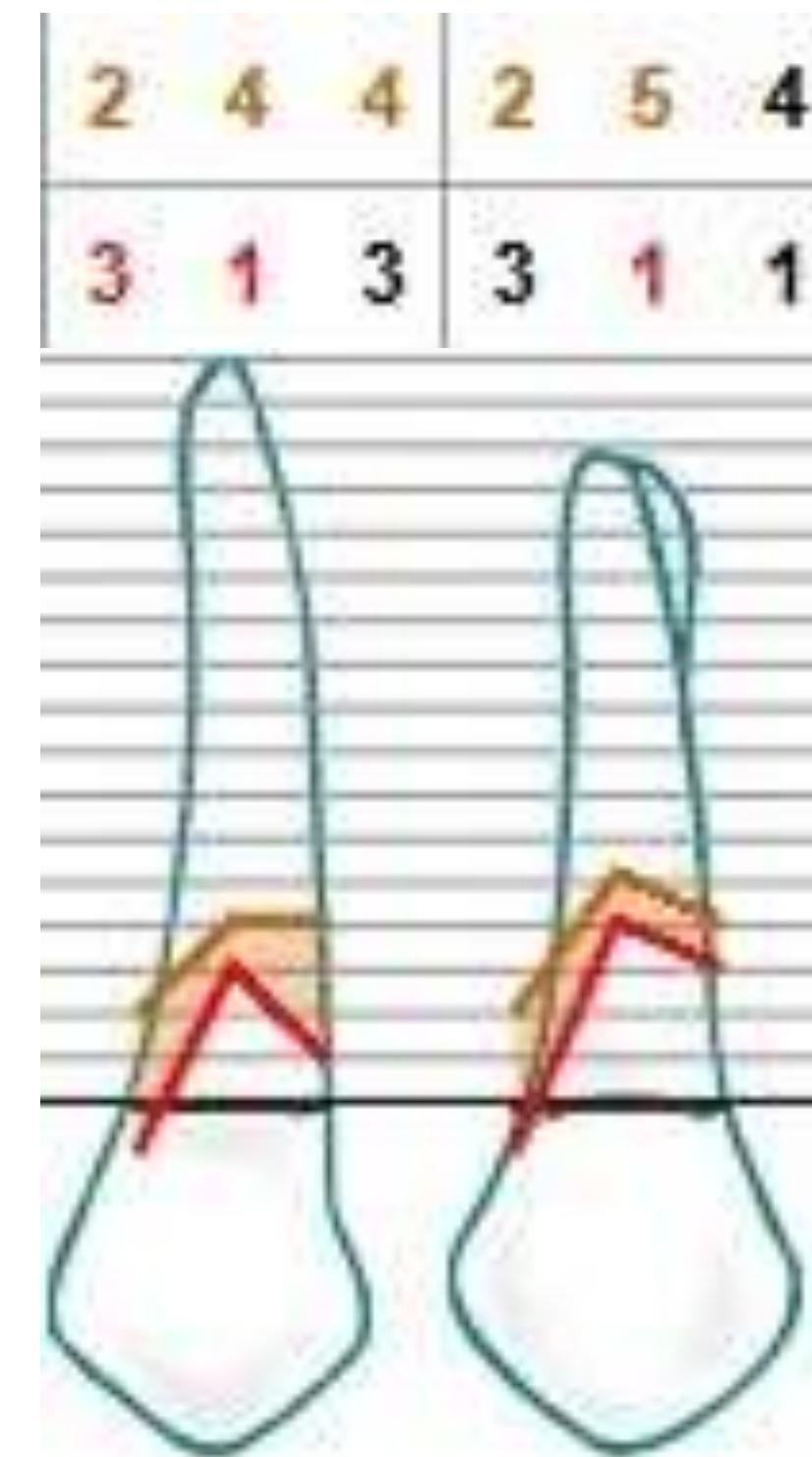
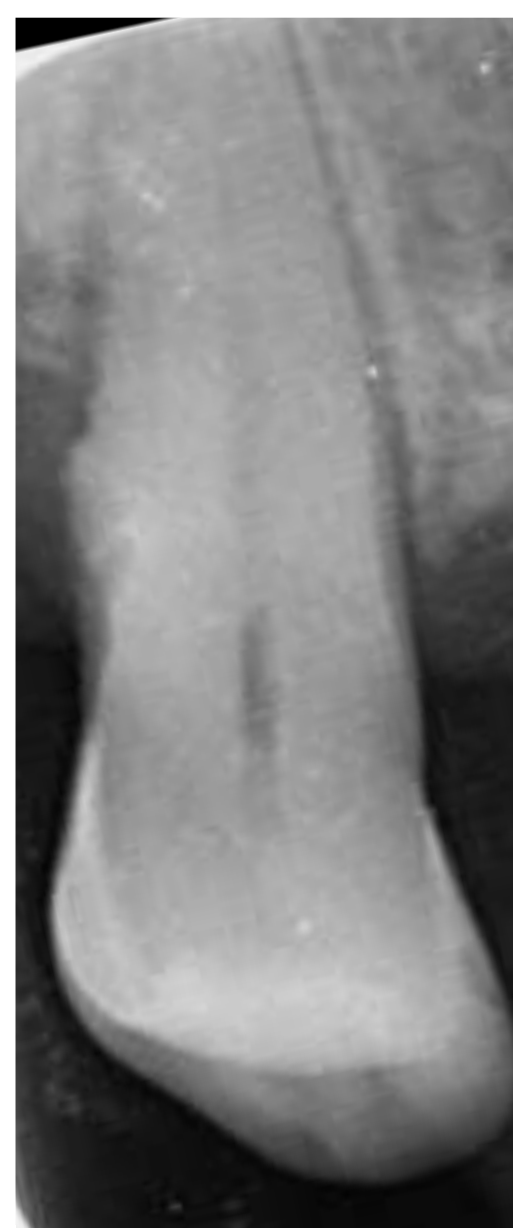
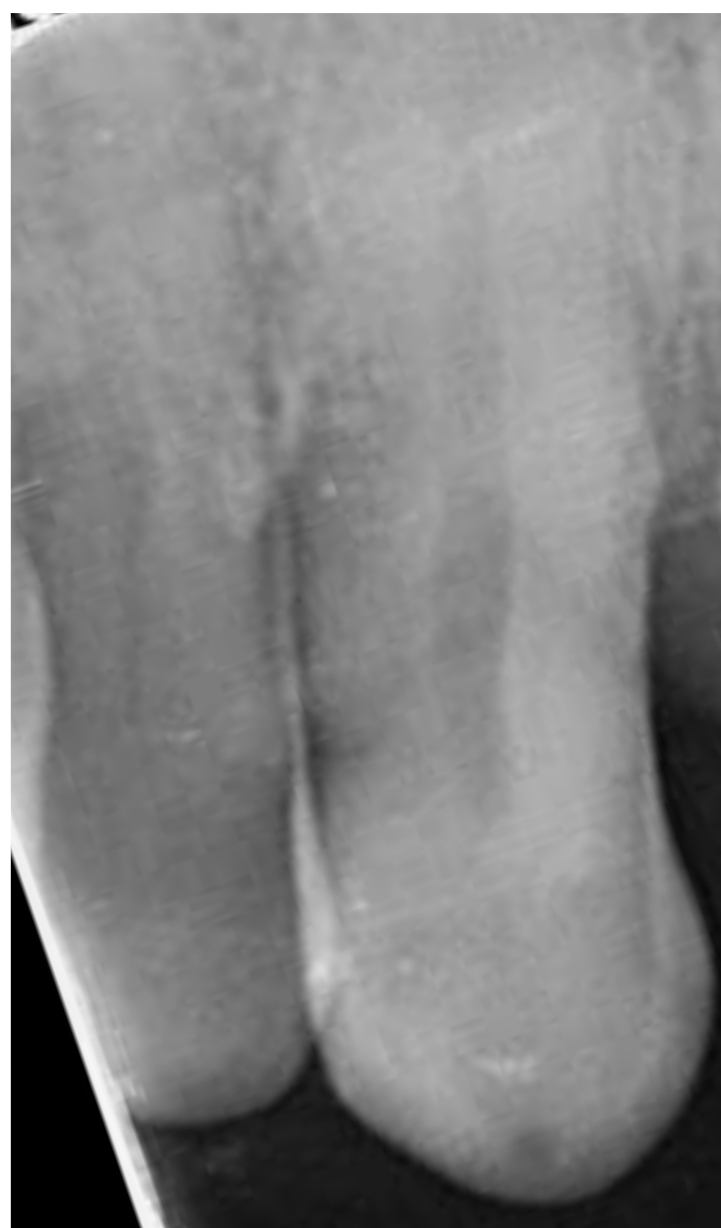
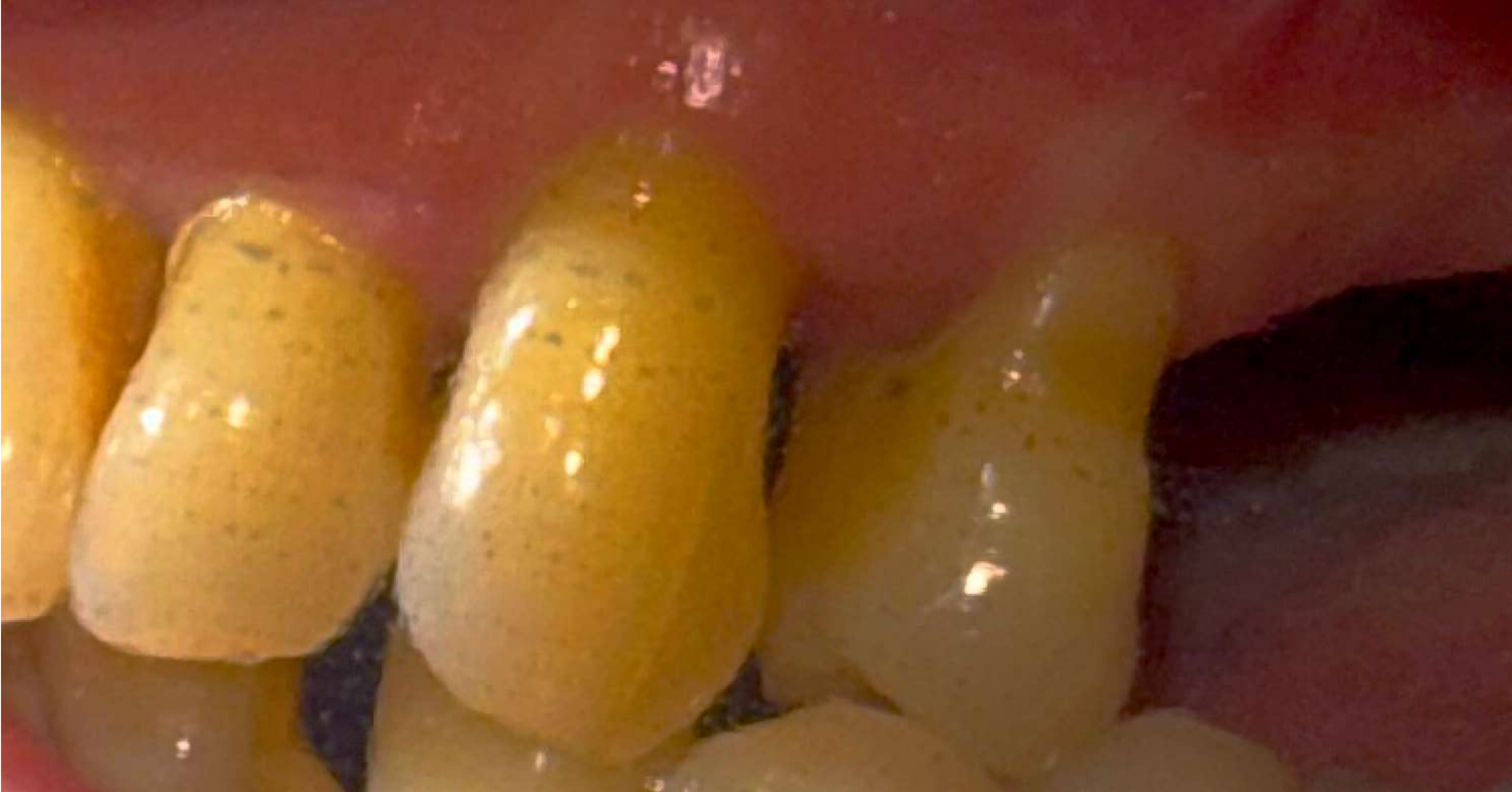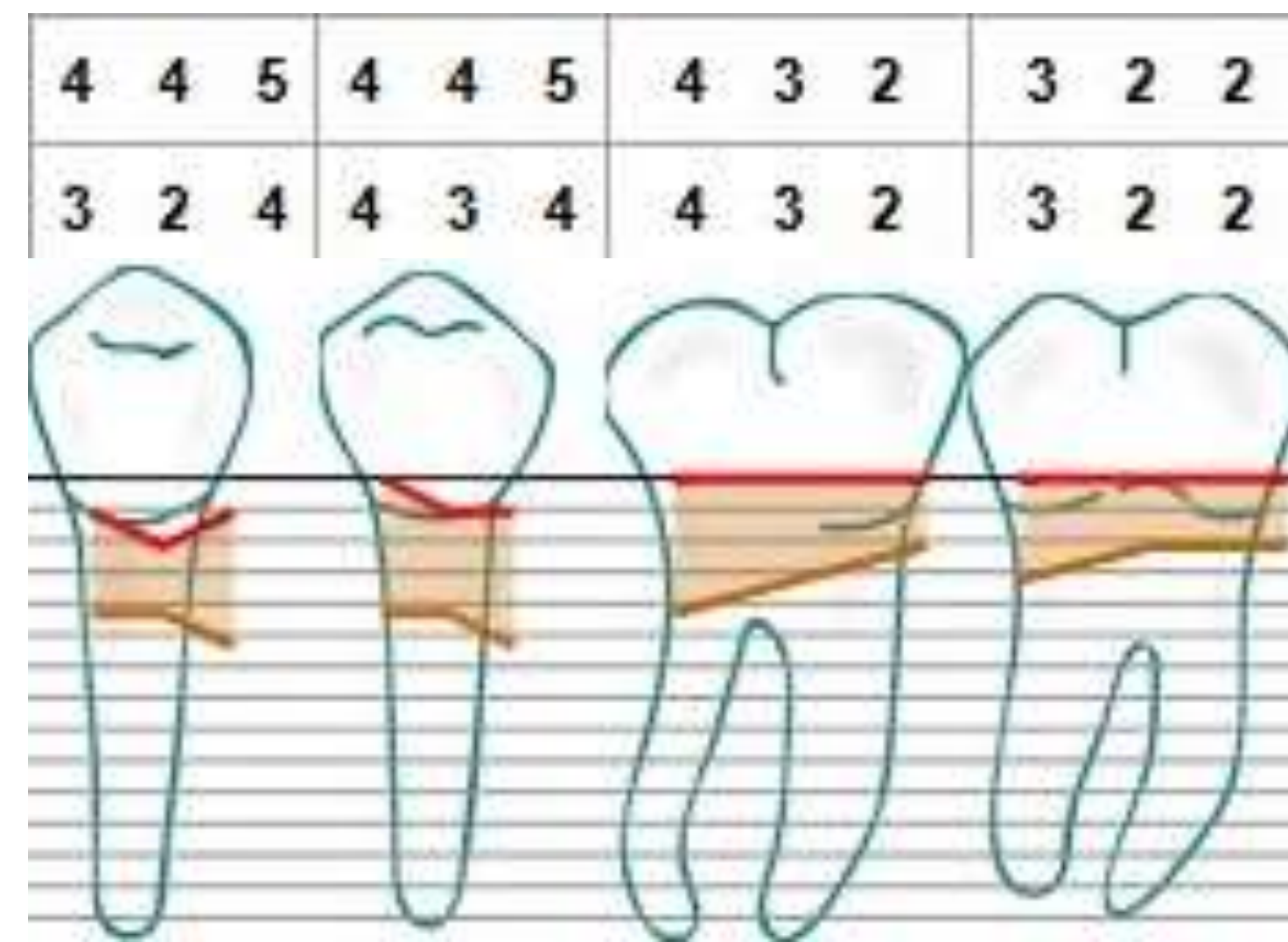
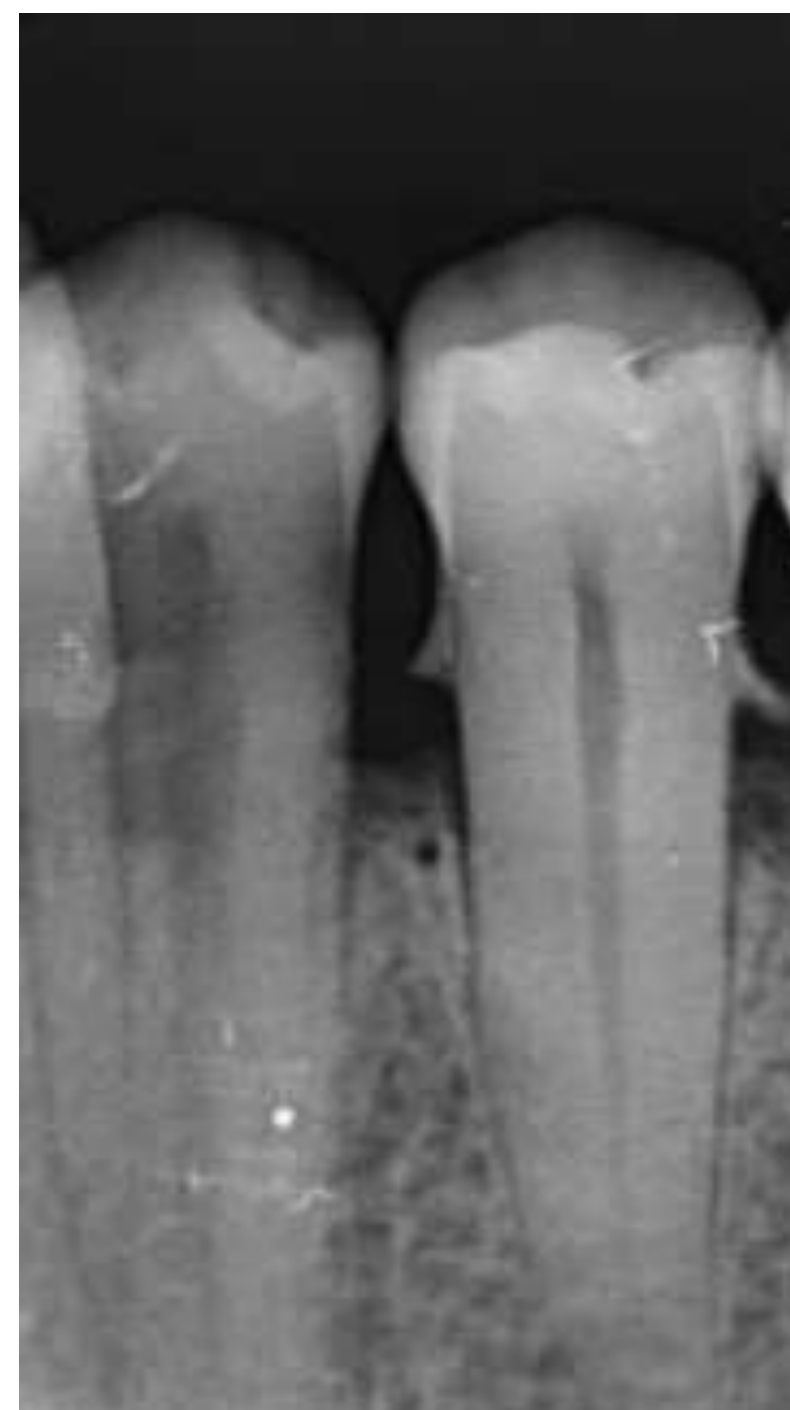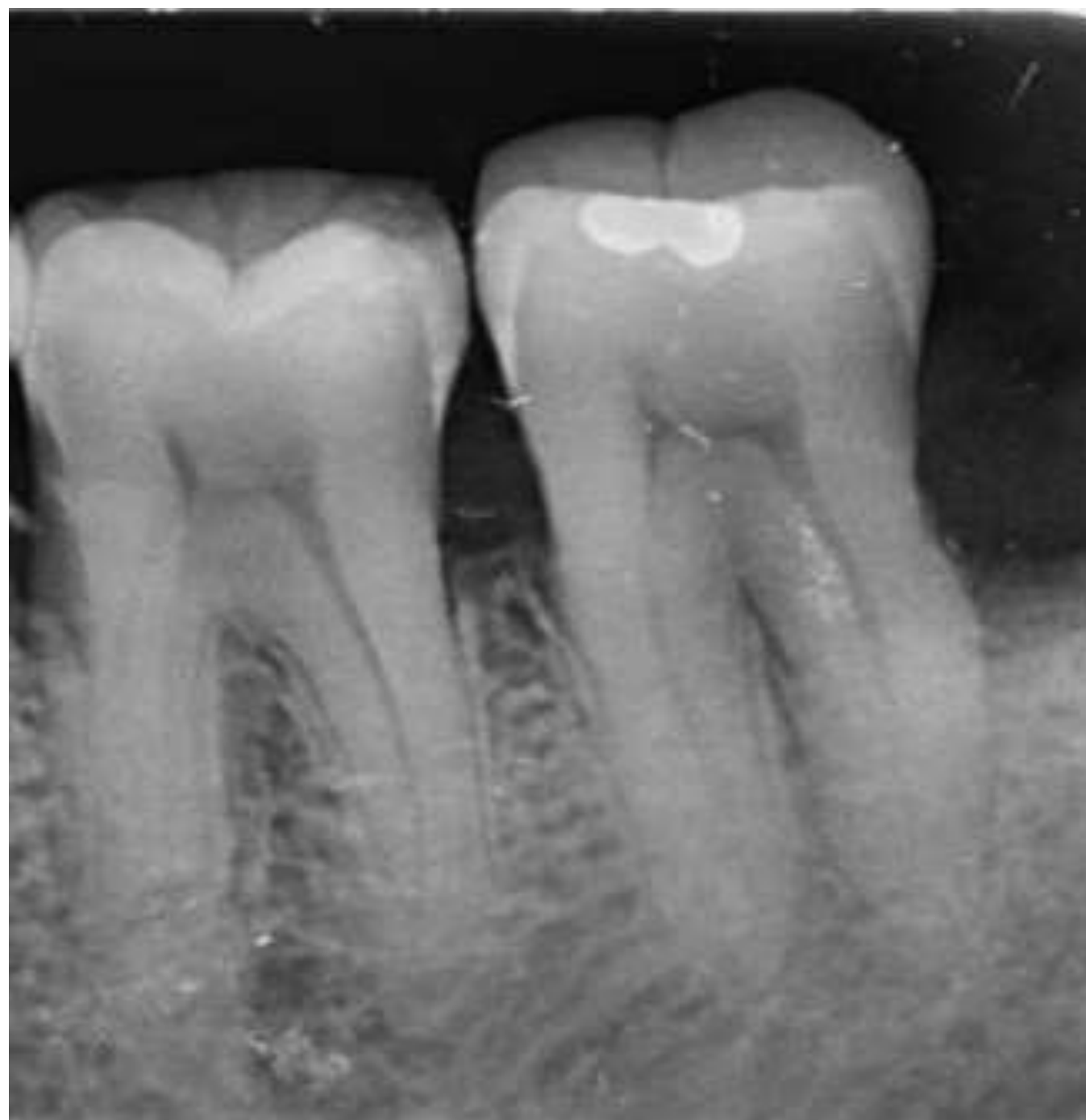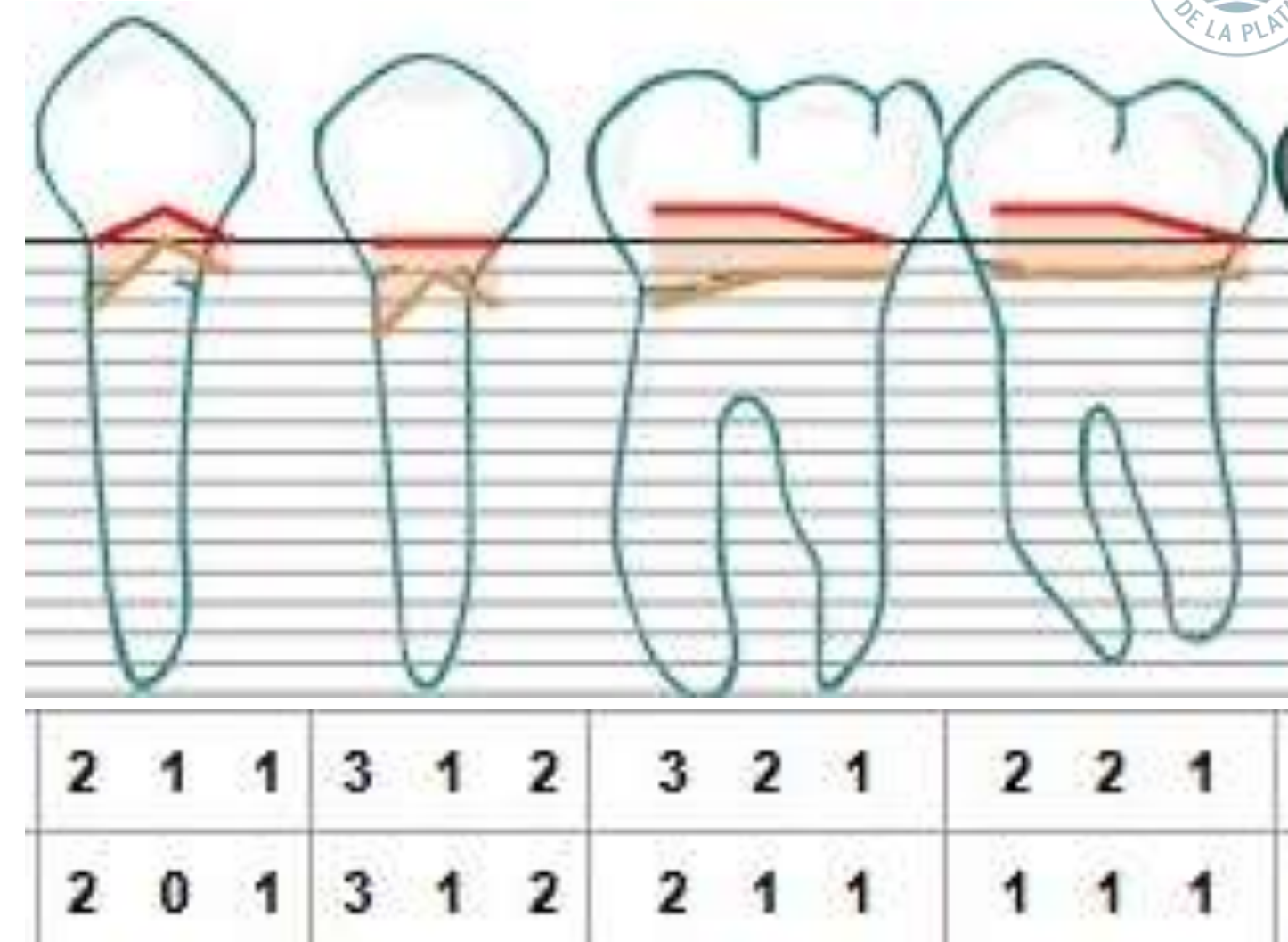
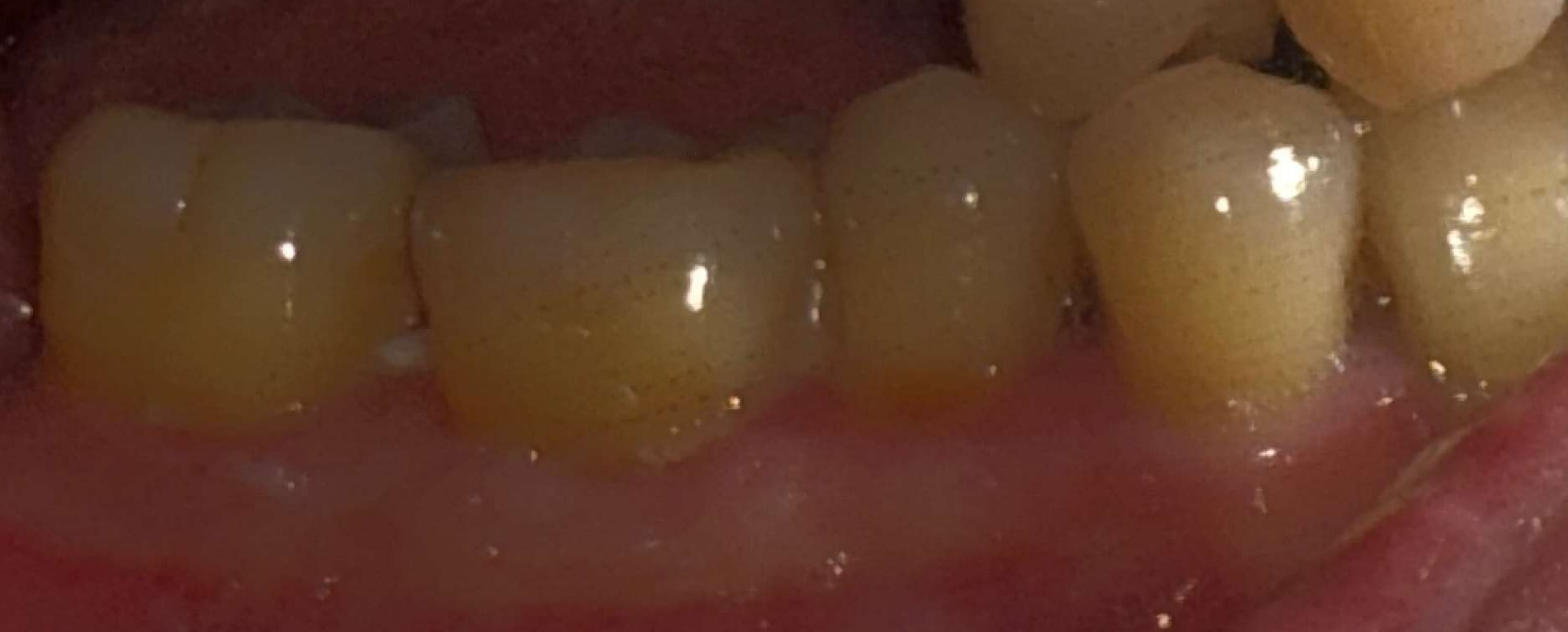5	4	5	5	5	10	7	2	6	4	1	2	3	1	2	2	4	4
4	1	3	4	2	5	5	1	5	4	1	3	3	1	3	3	1	3

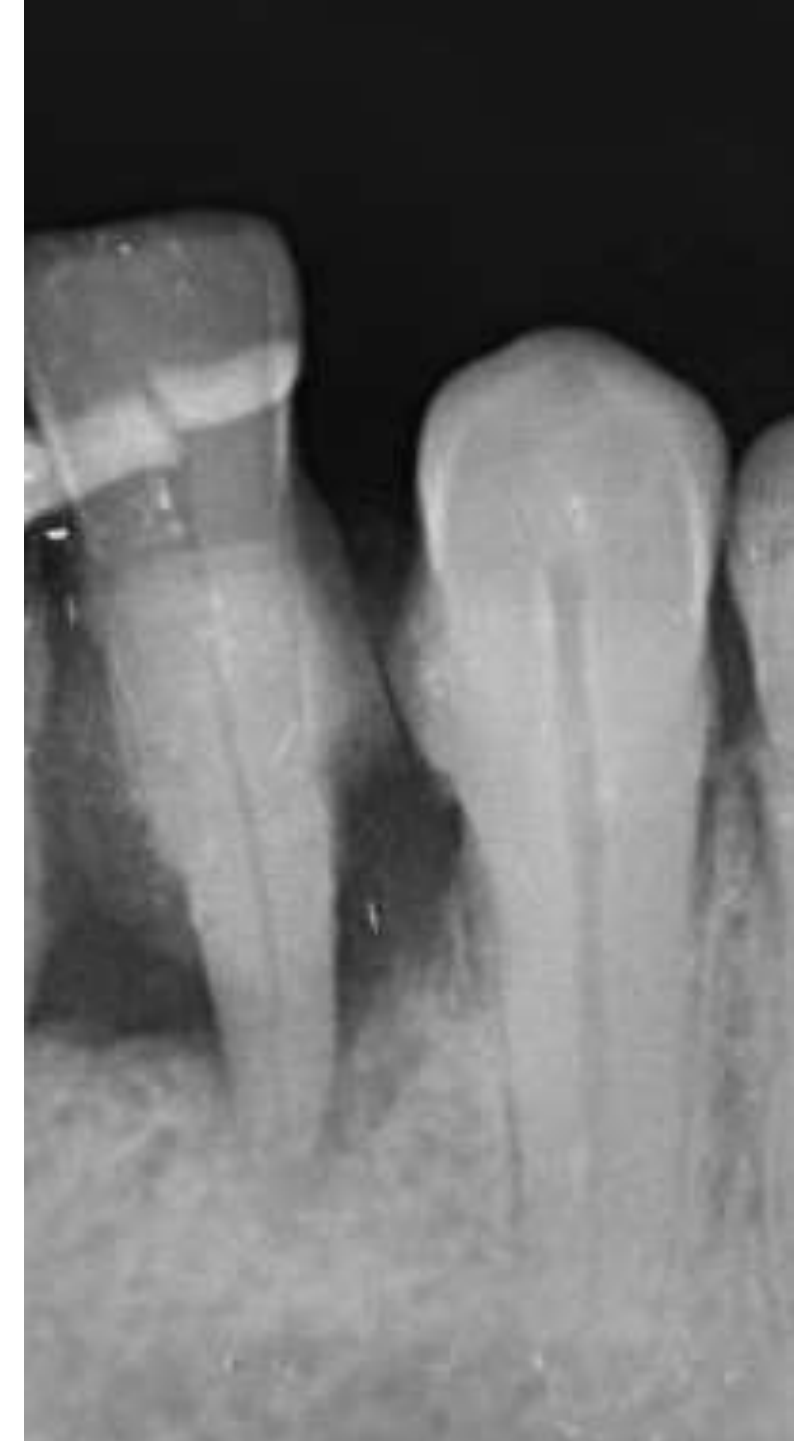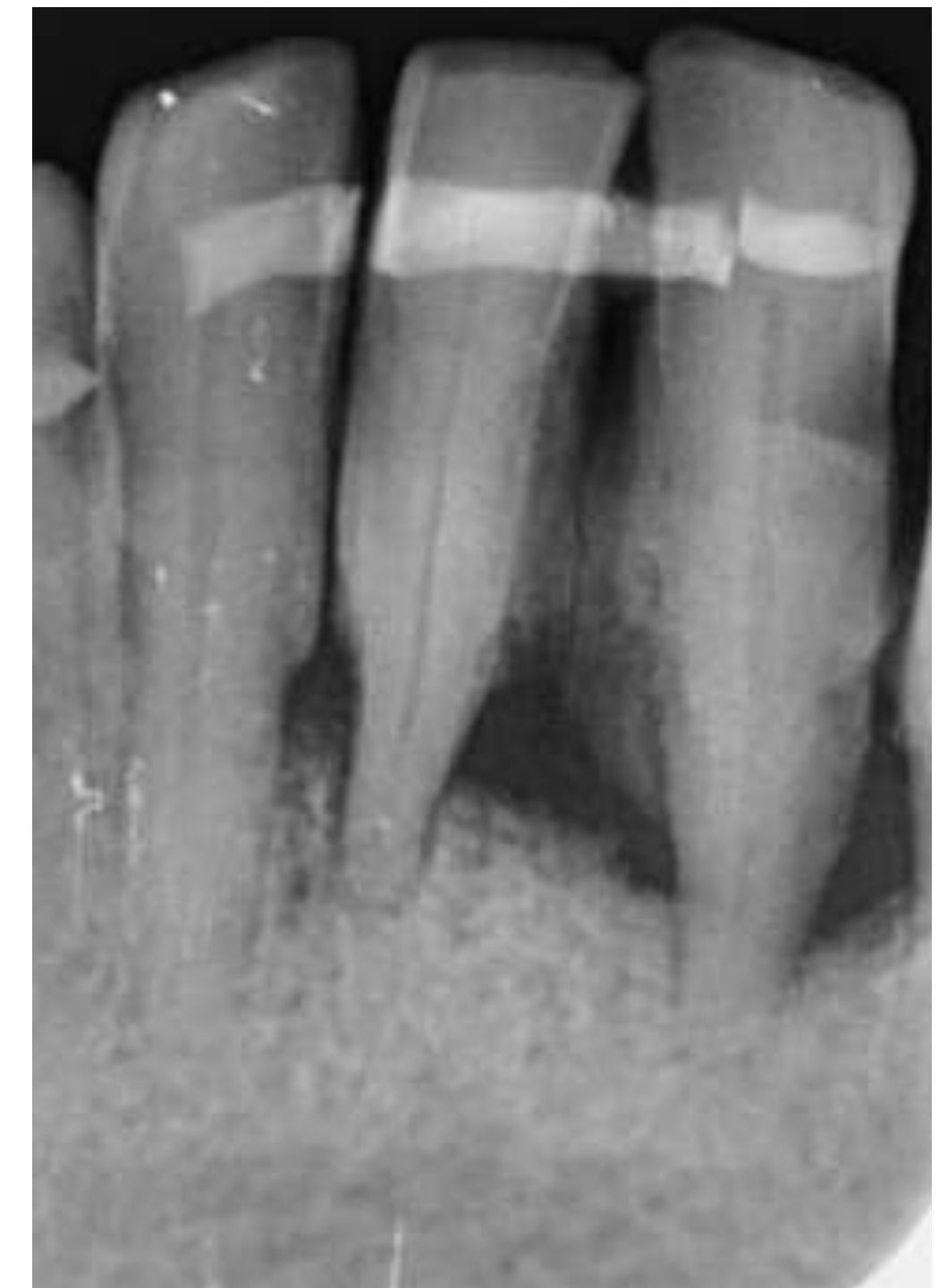
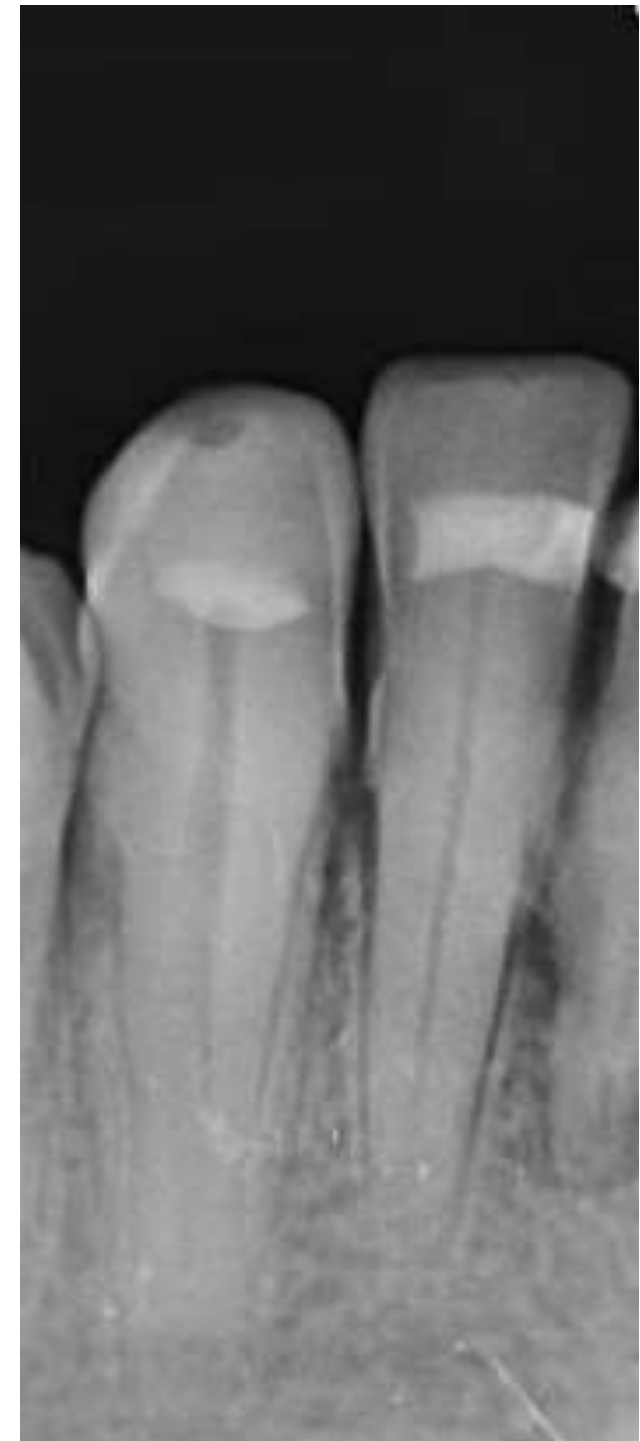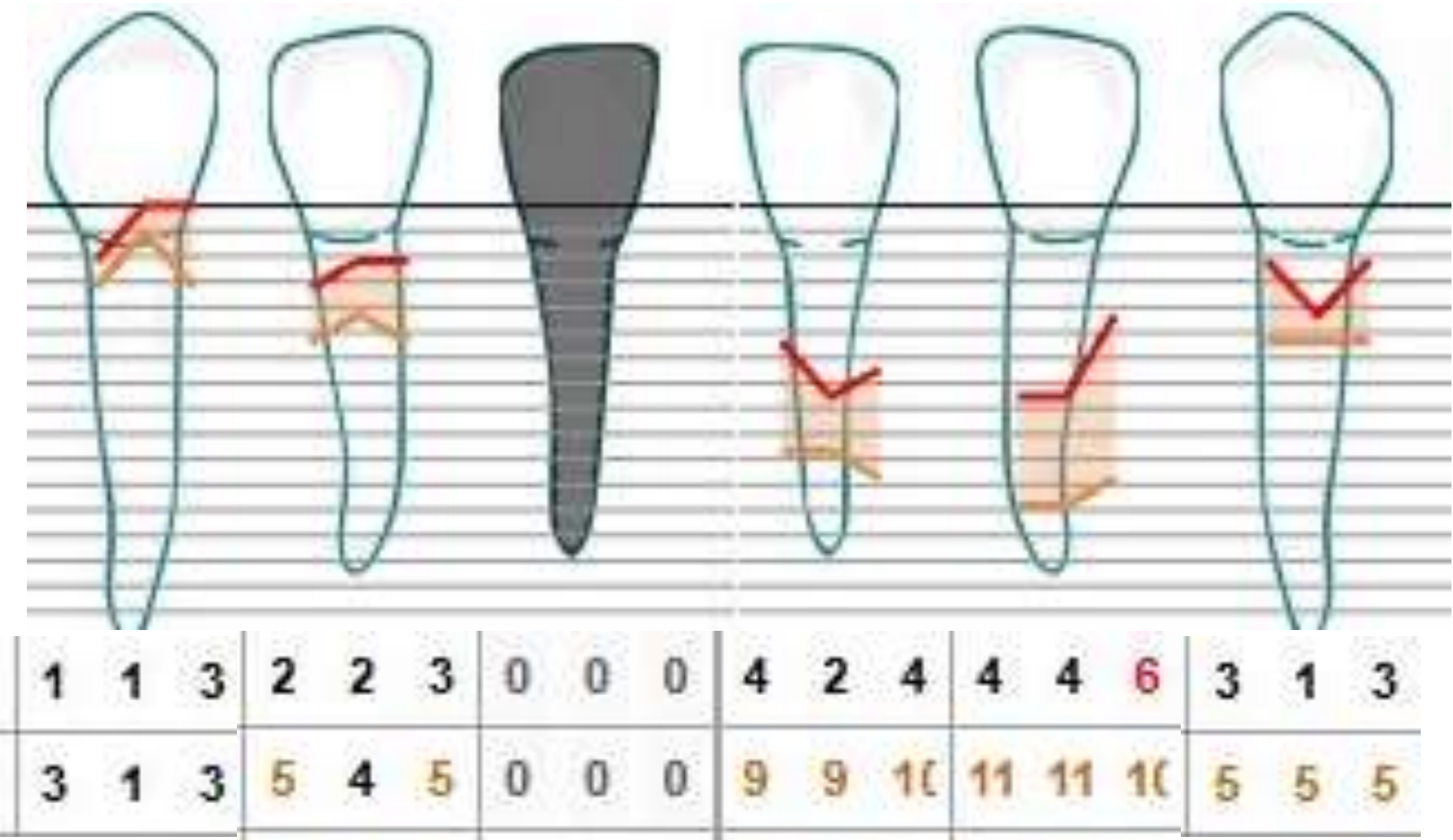


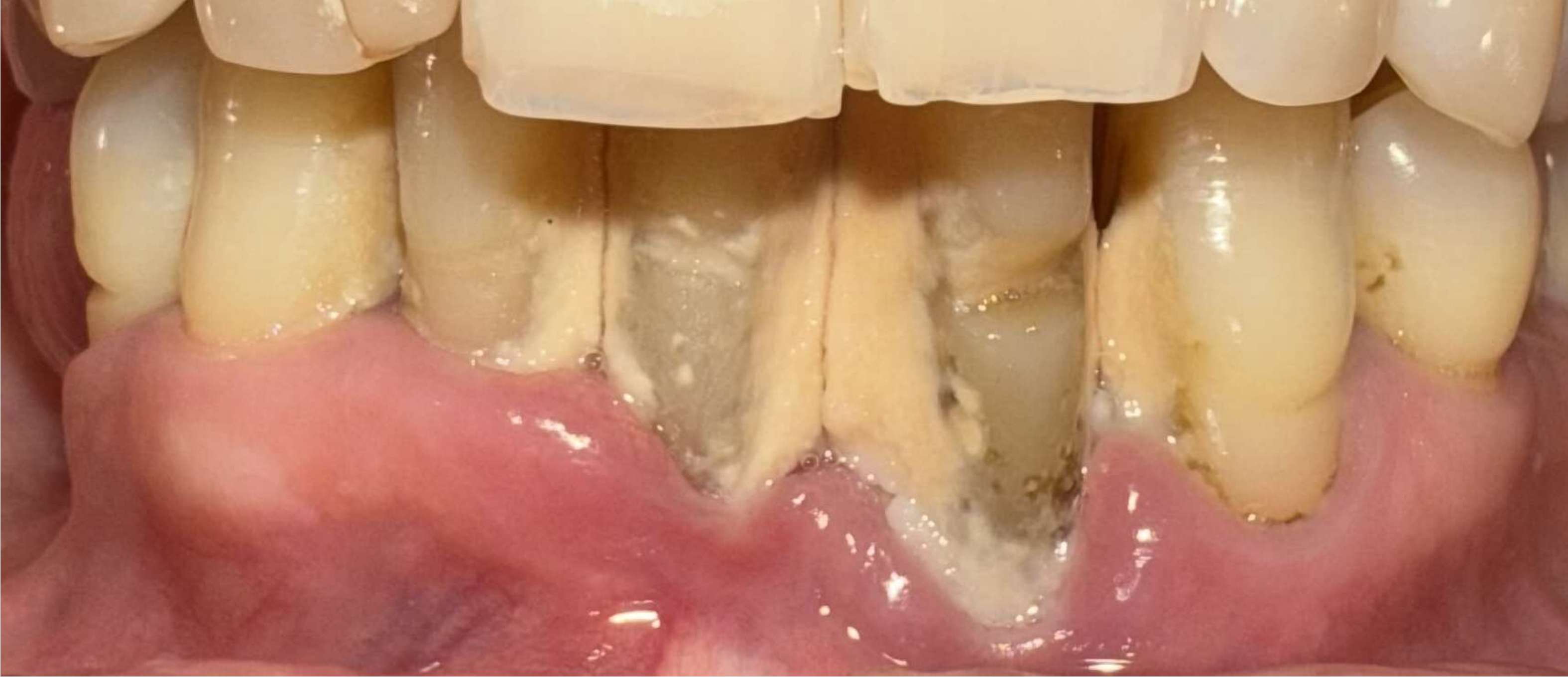

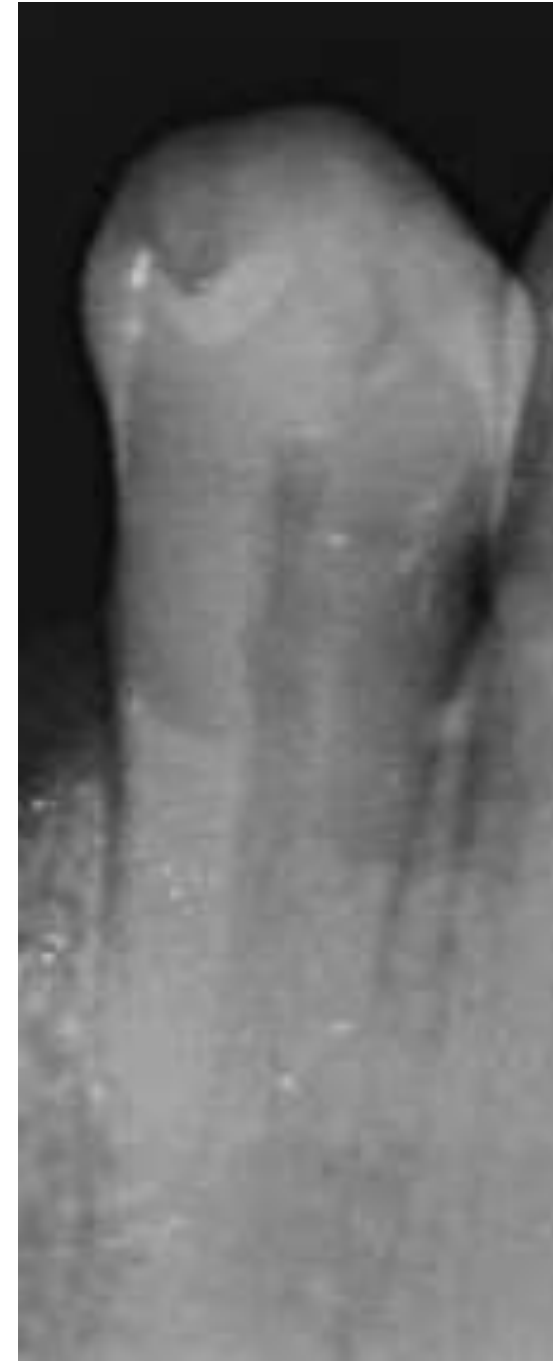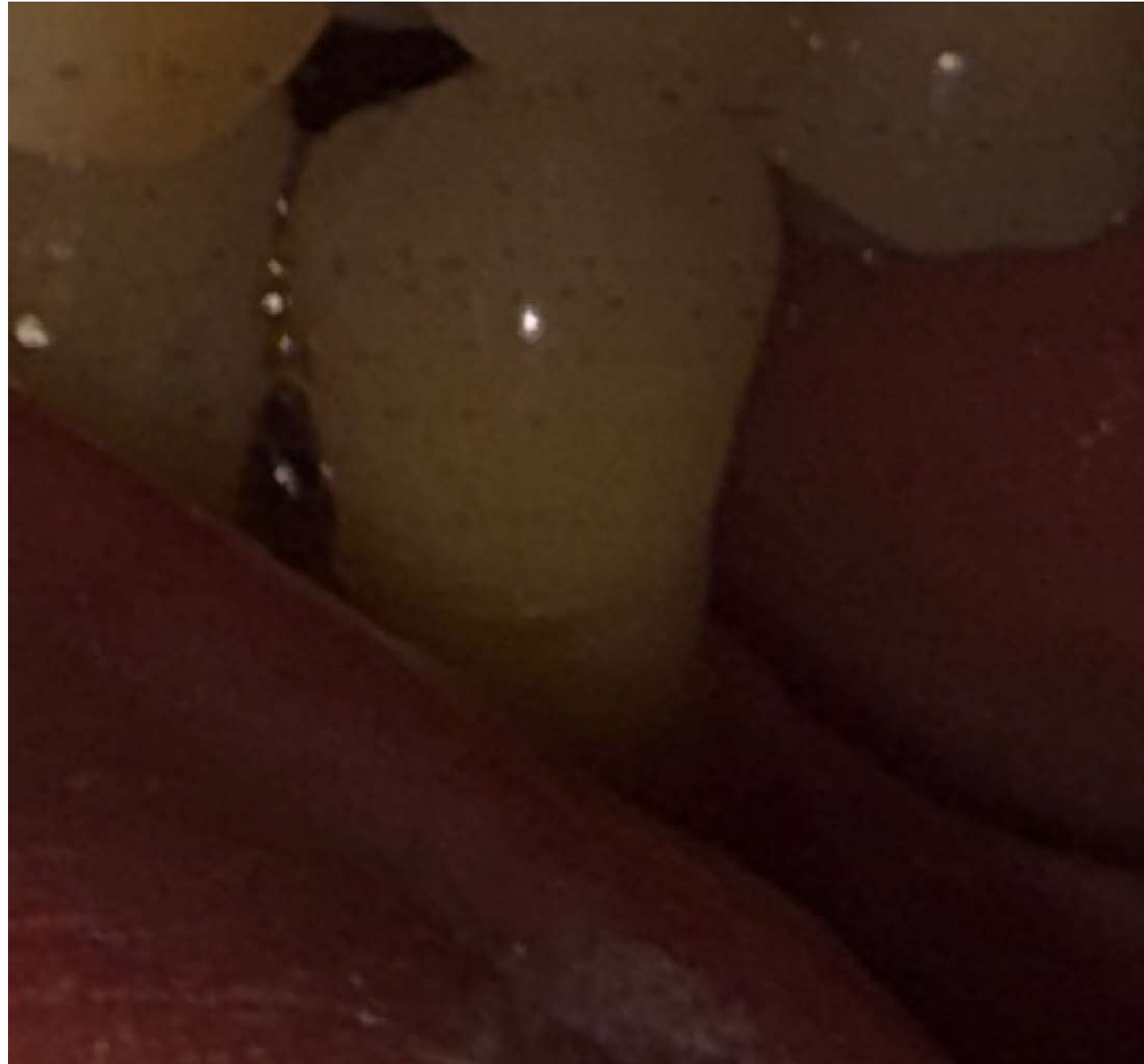5	4	4	5	6	6	7	7	6	1	1	1	1	1	1	1	5	5	4
8	7	6	8	7	9	11	10	8	1	1	1	0	0	1	5	6	6	











Diagnóstico

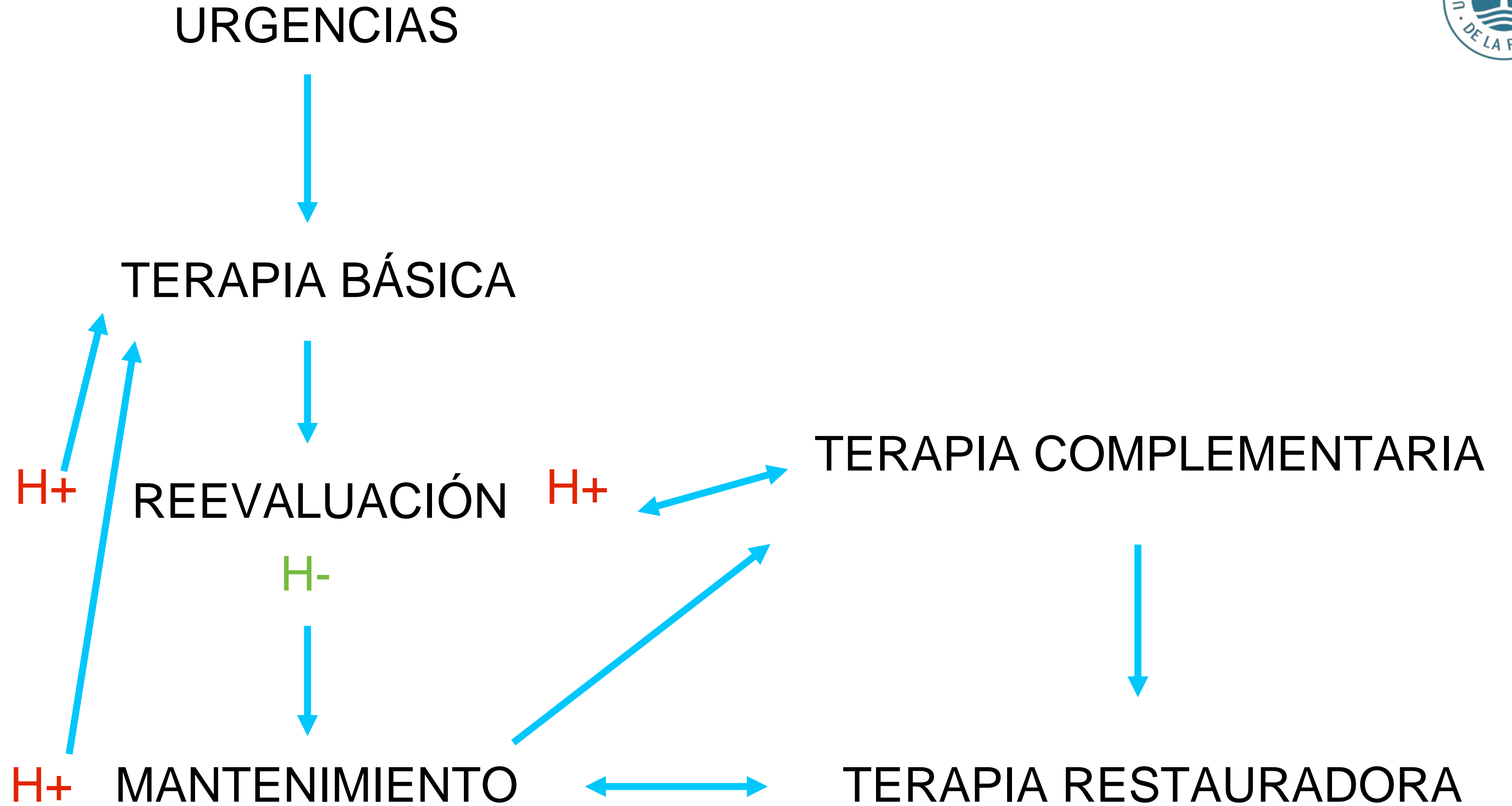
* Periodontitis Estadio IV, Grado C, Generalizada

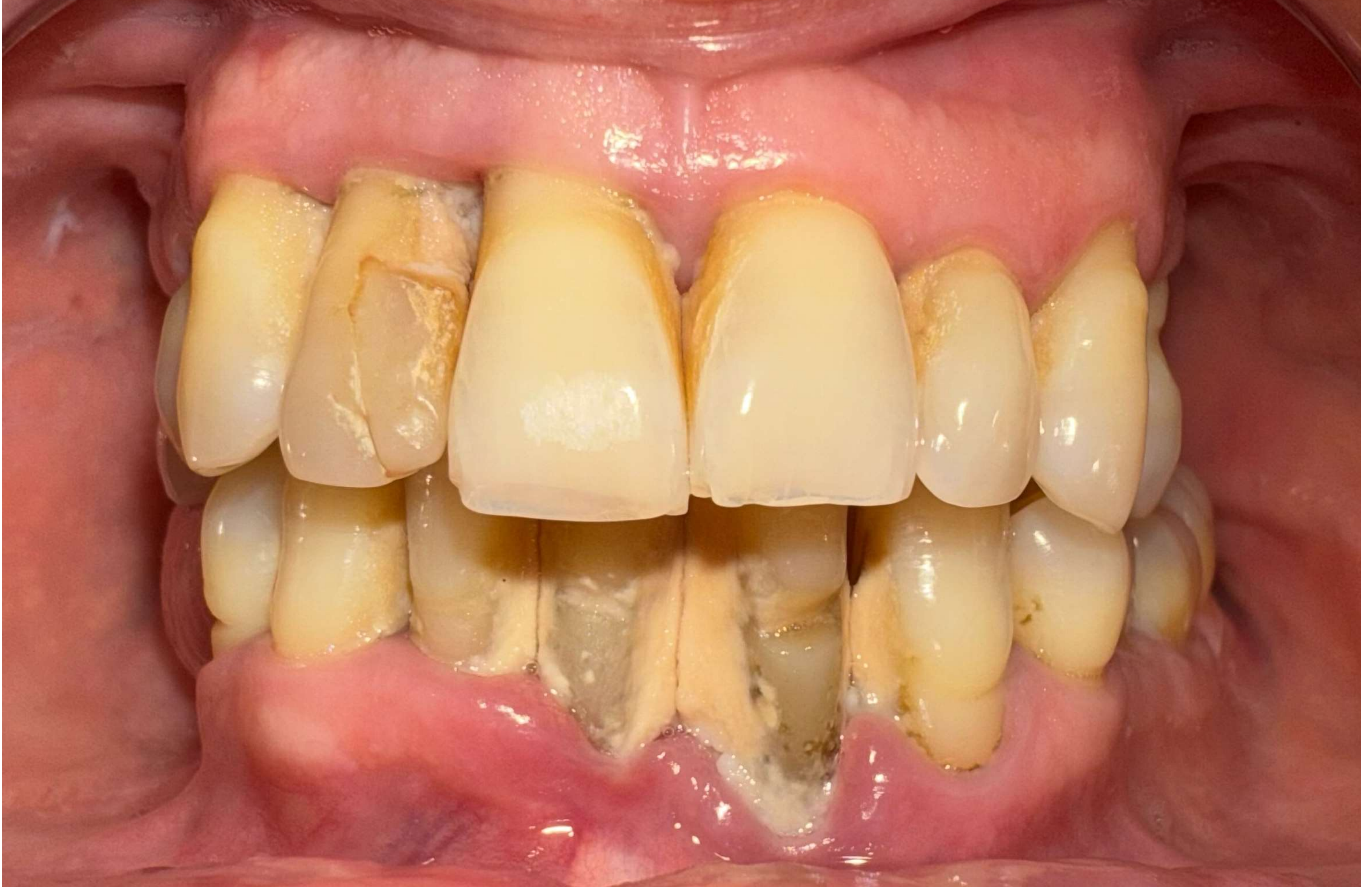*Classification of Periodontal and Peri-Implant Diseases and Conditions -
World Workshop 2017*

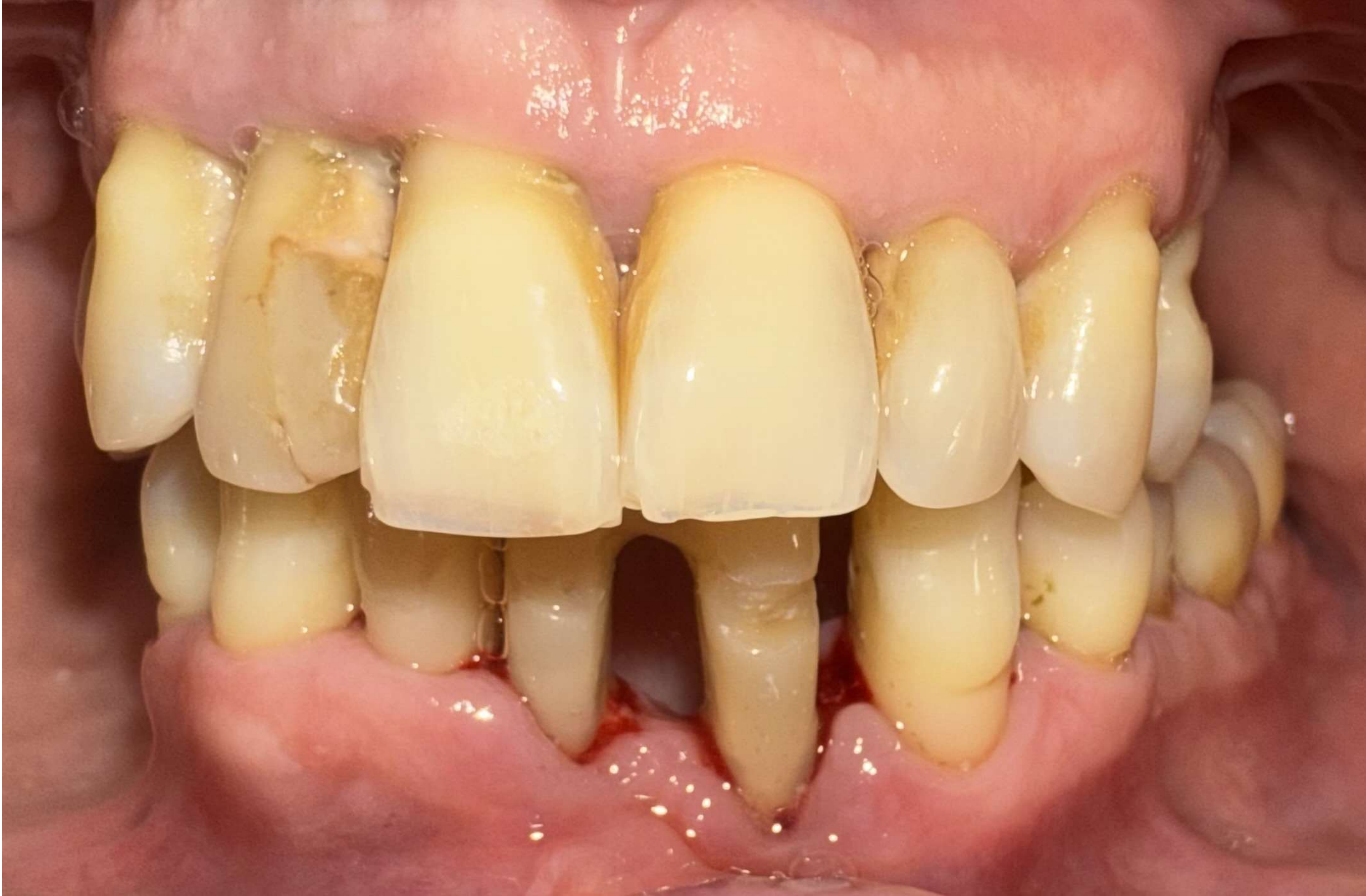

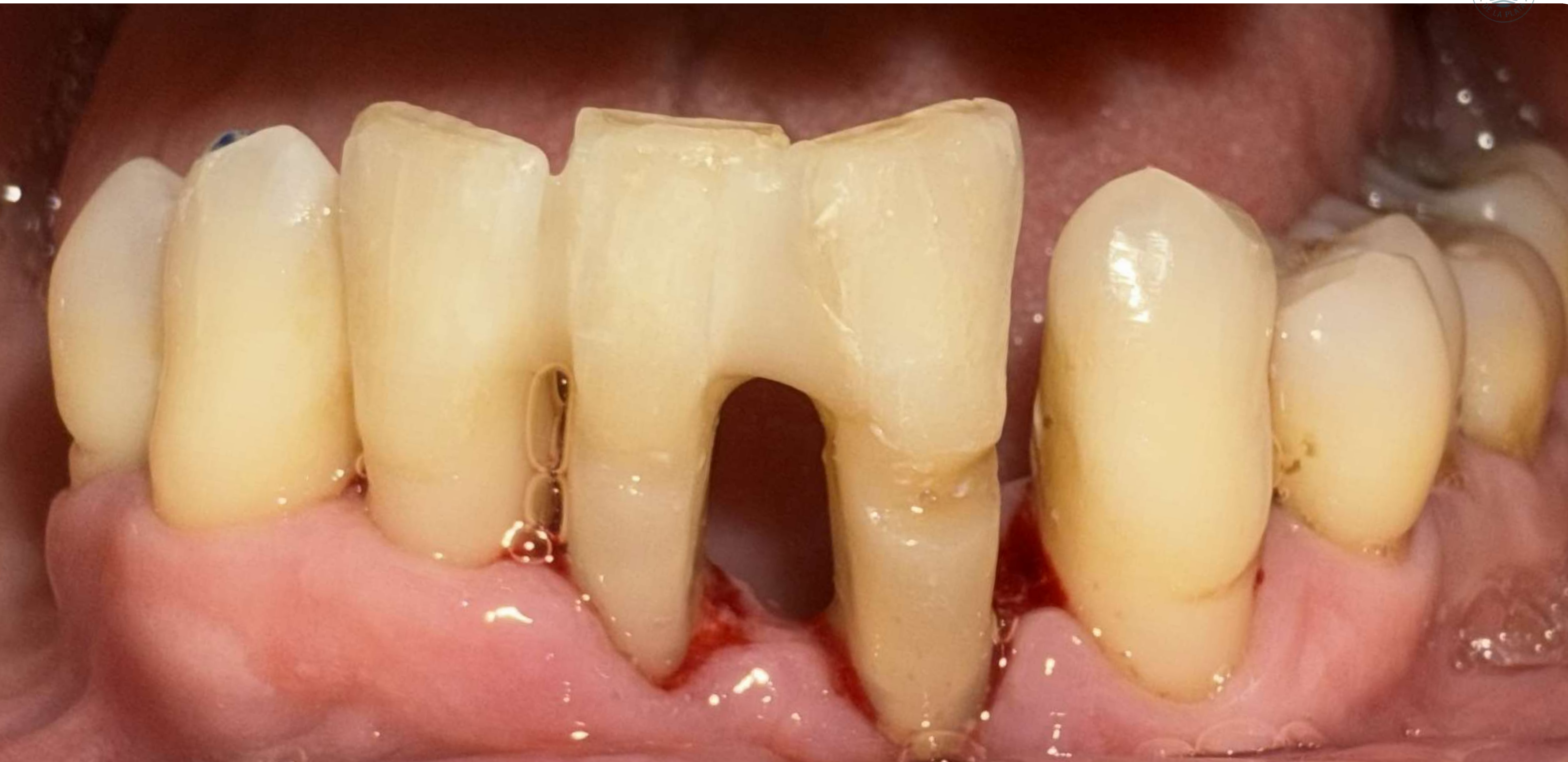Pronóstico

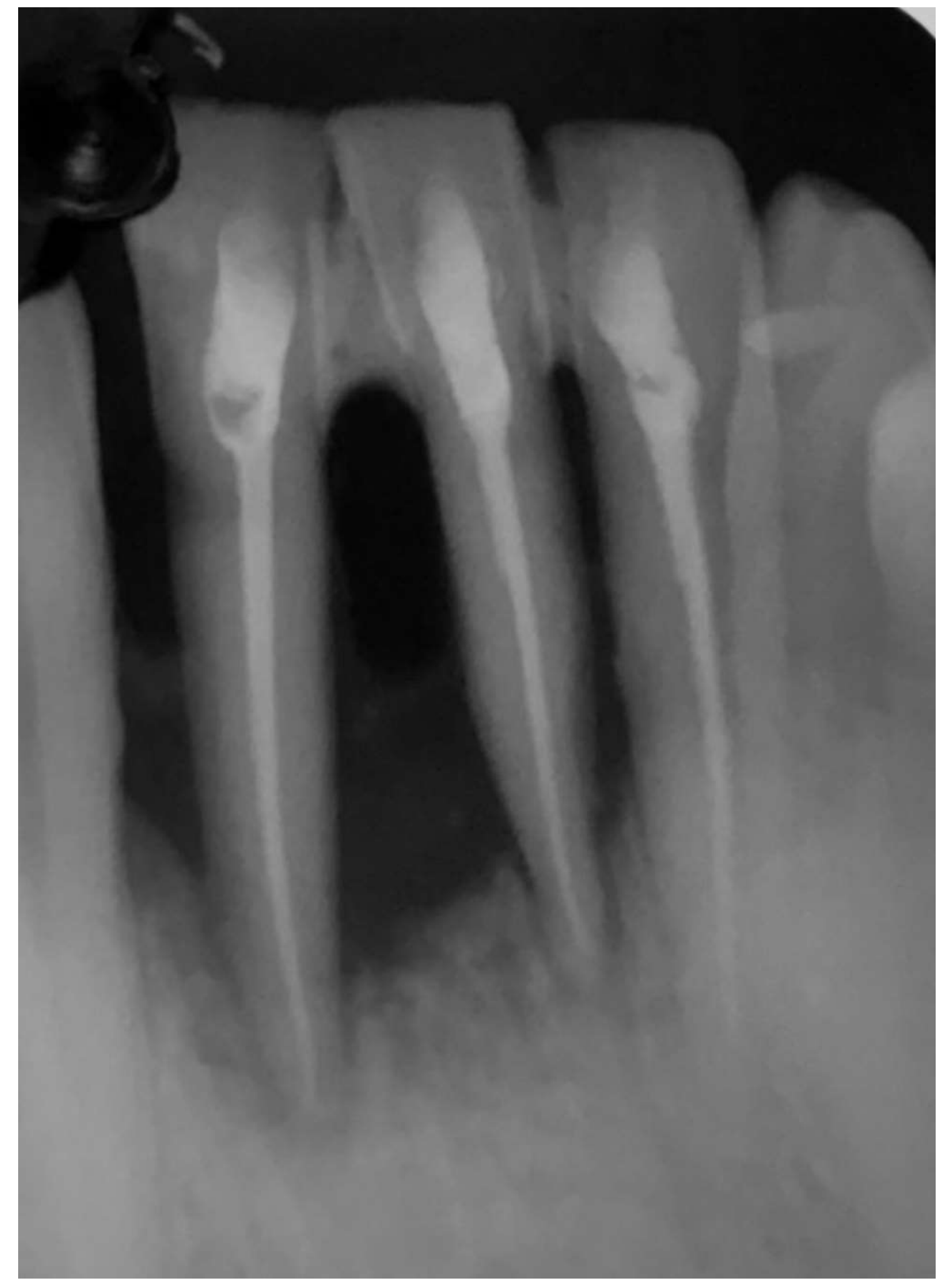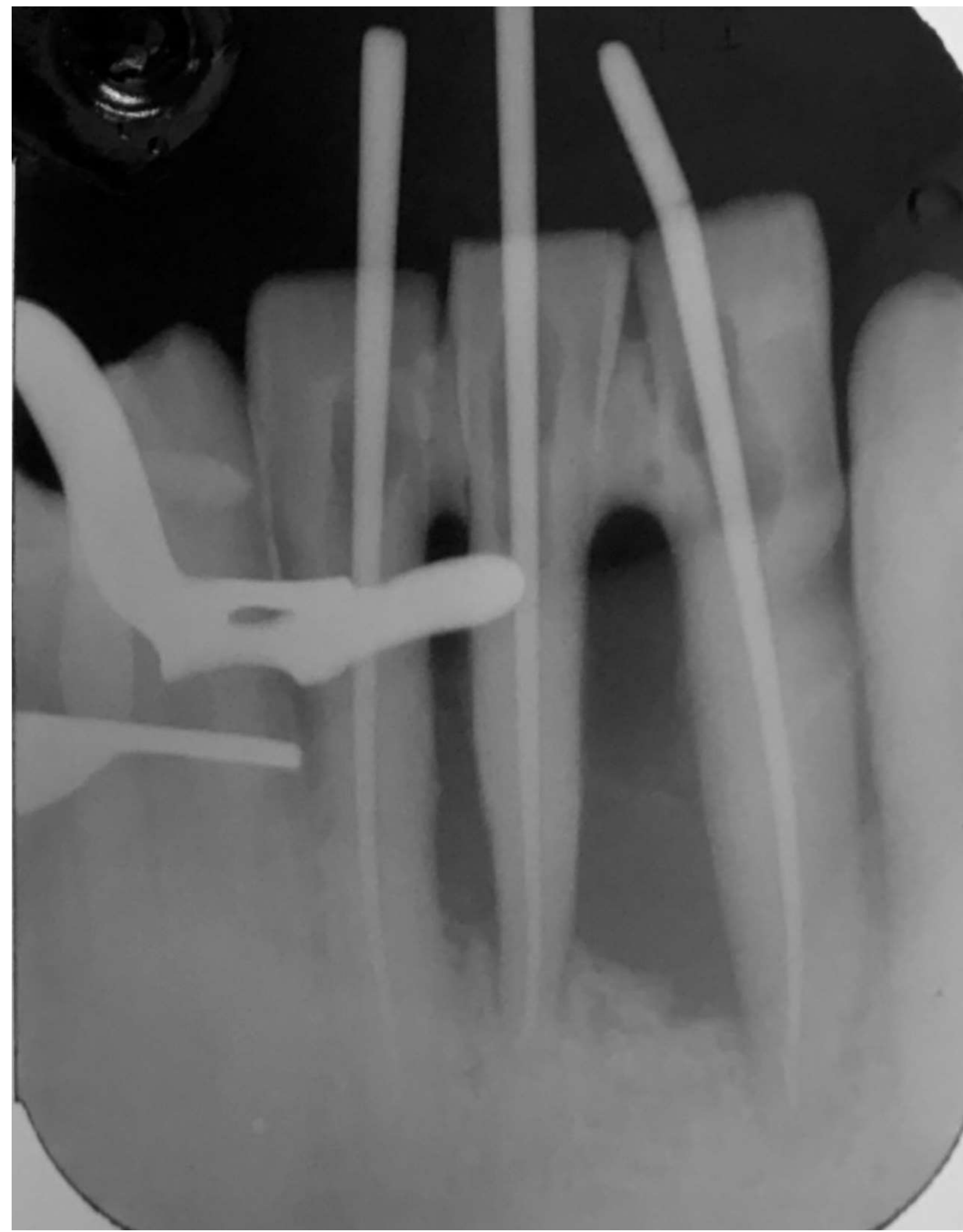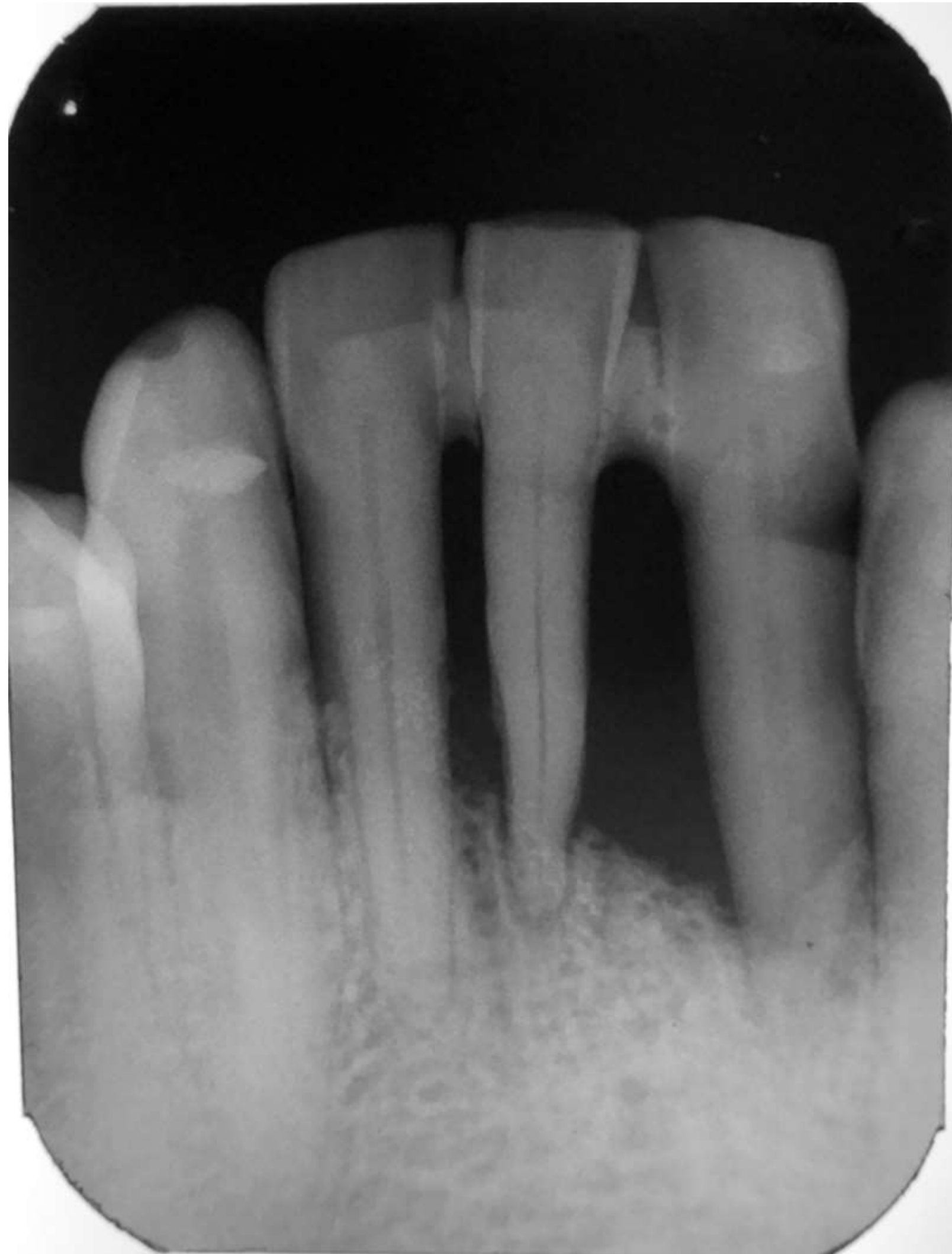Dudoso: 16-15-14-13-12-11-21-22-23-24-25-34-33-32-31-42-43-44-45-46-47

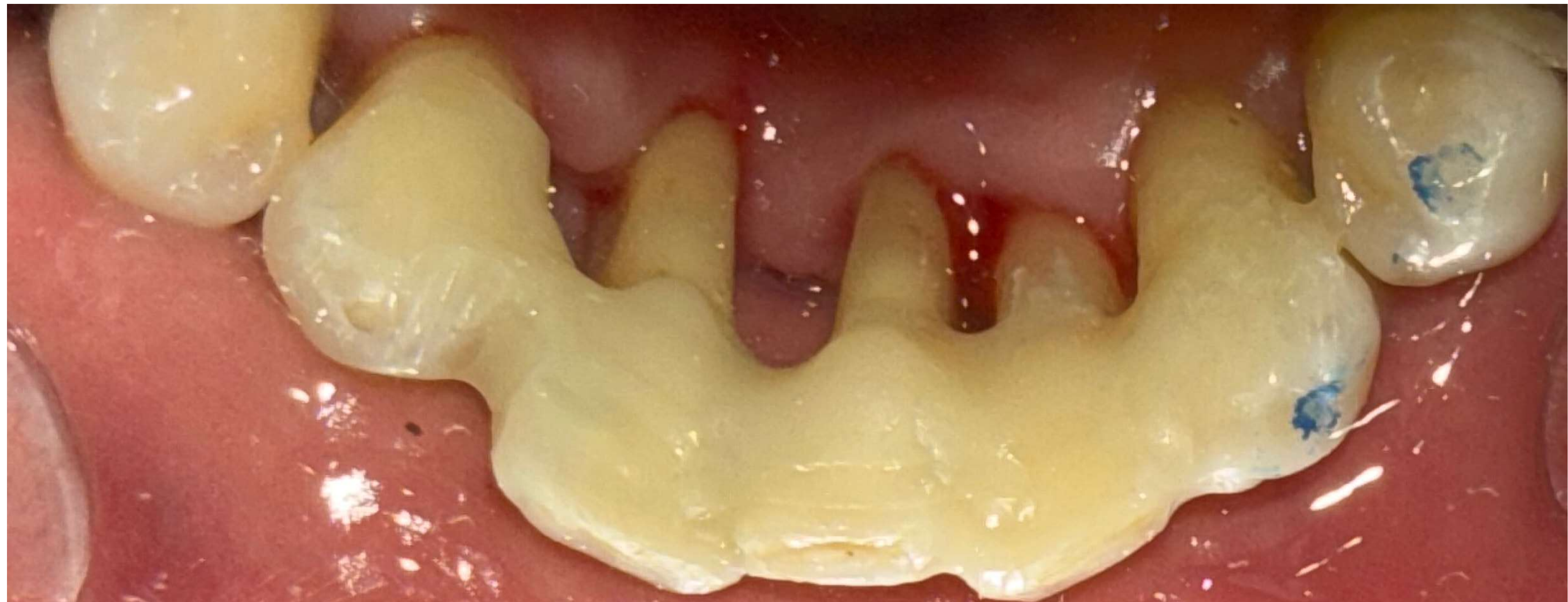
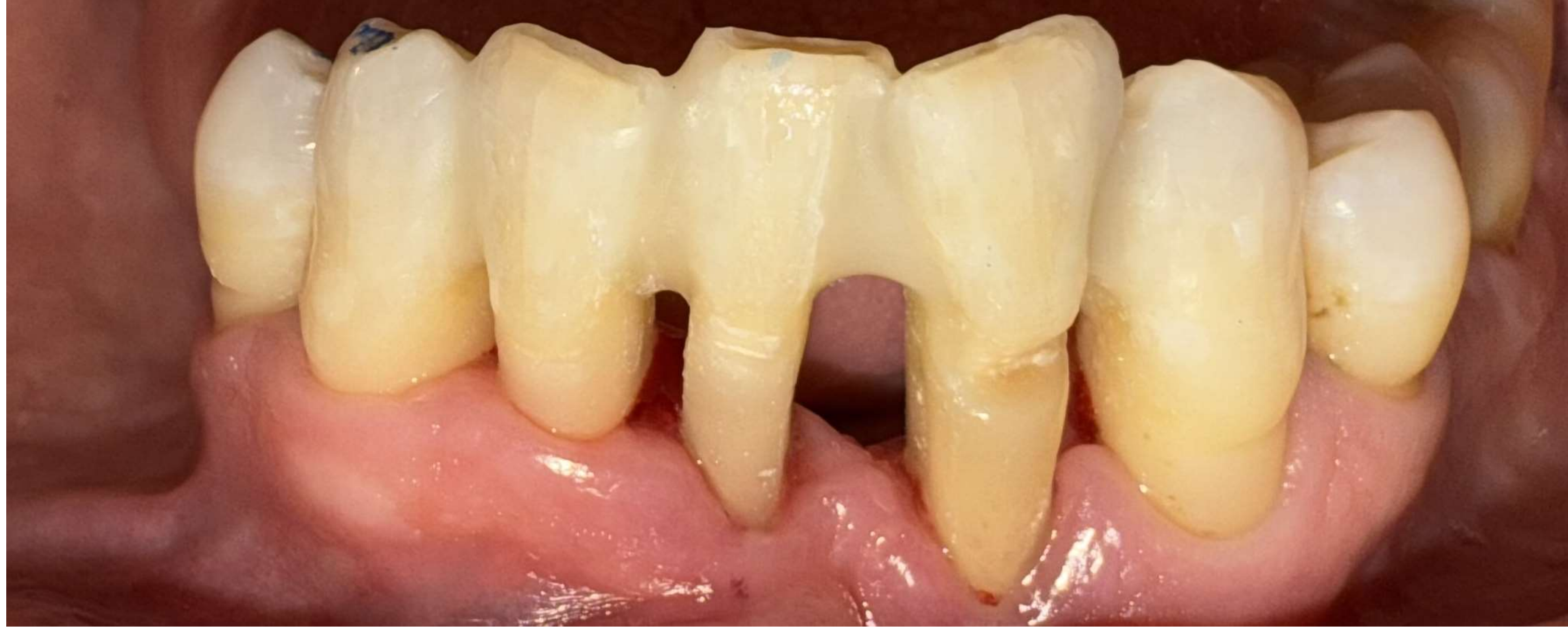


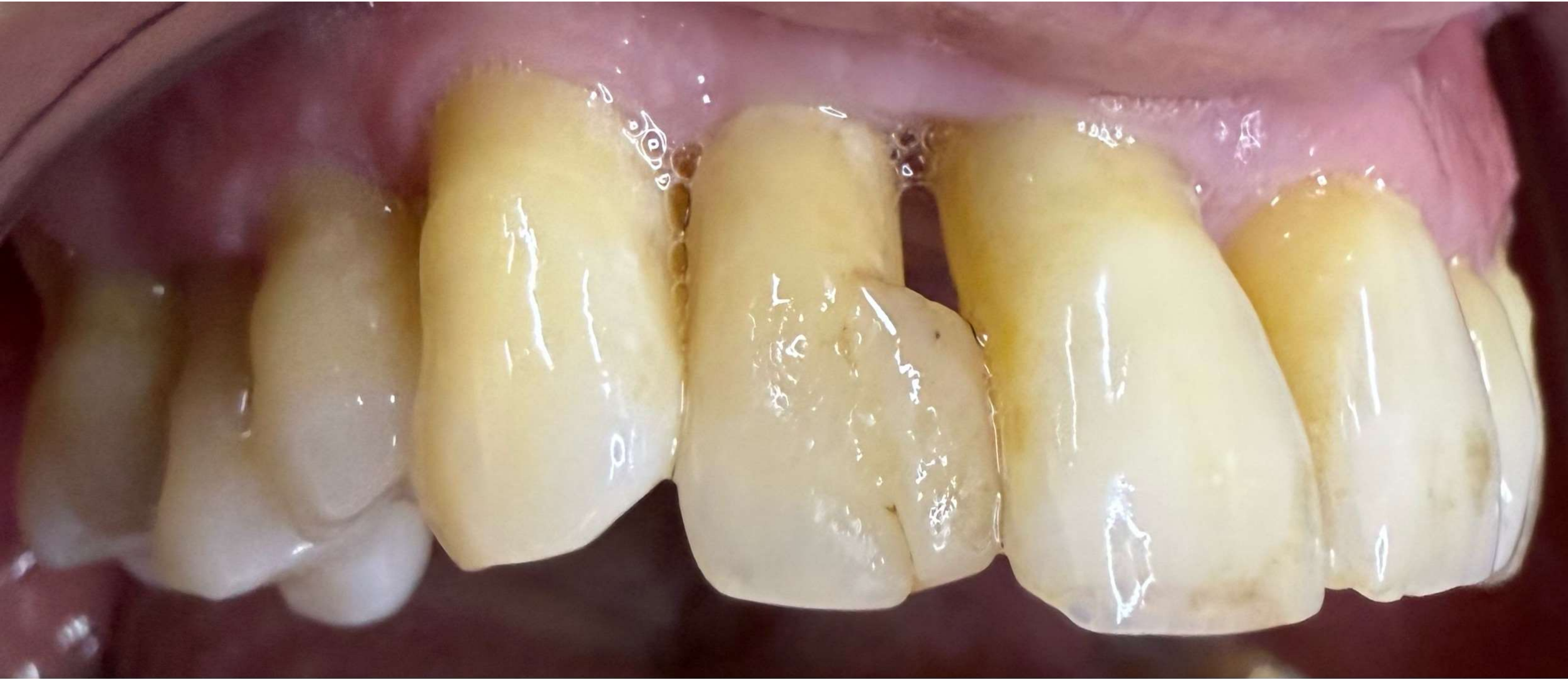


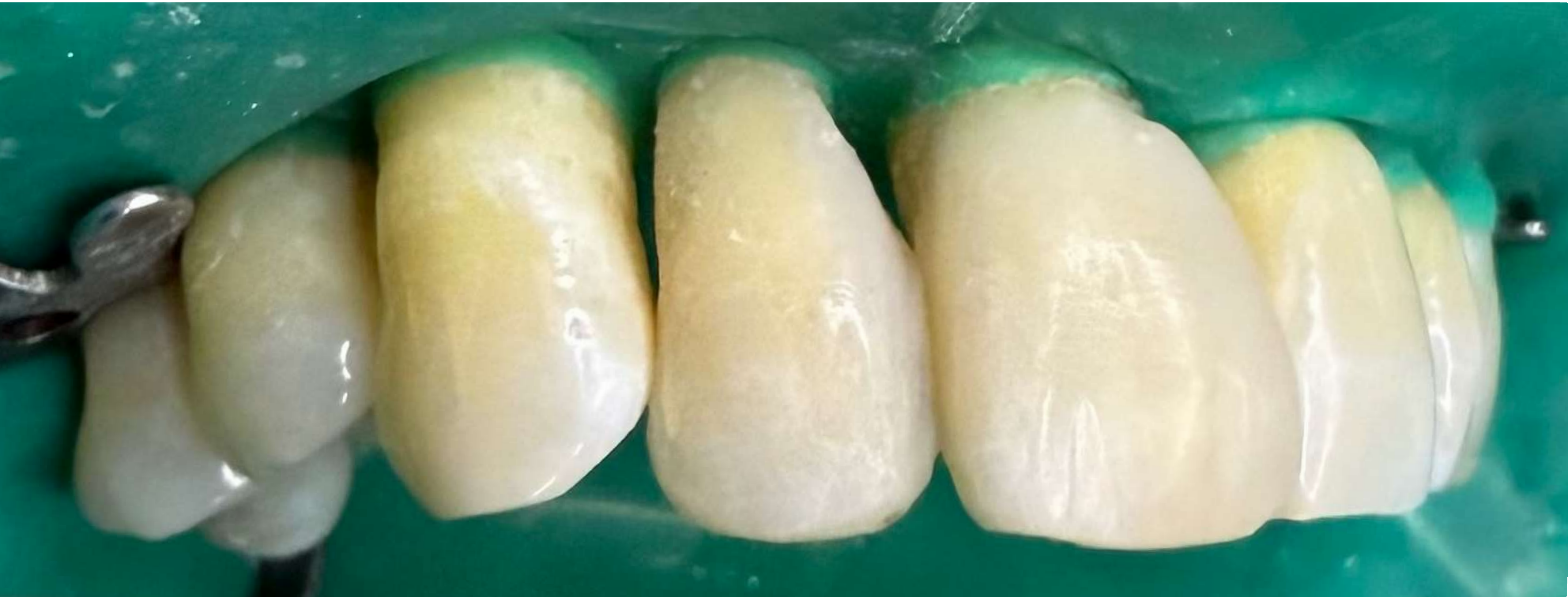


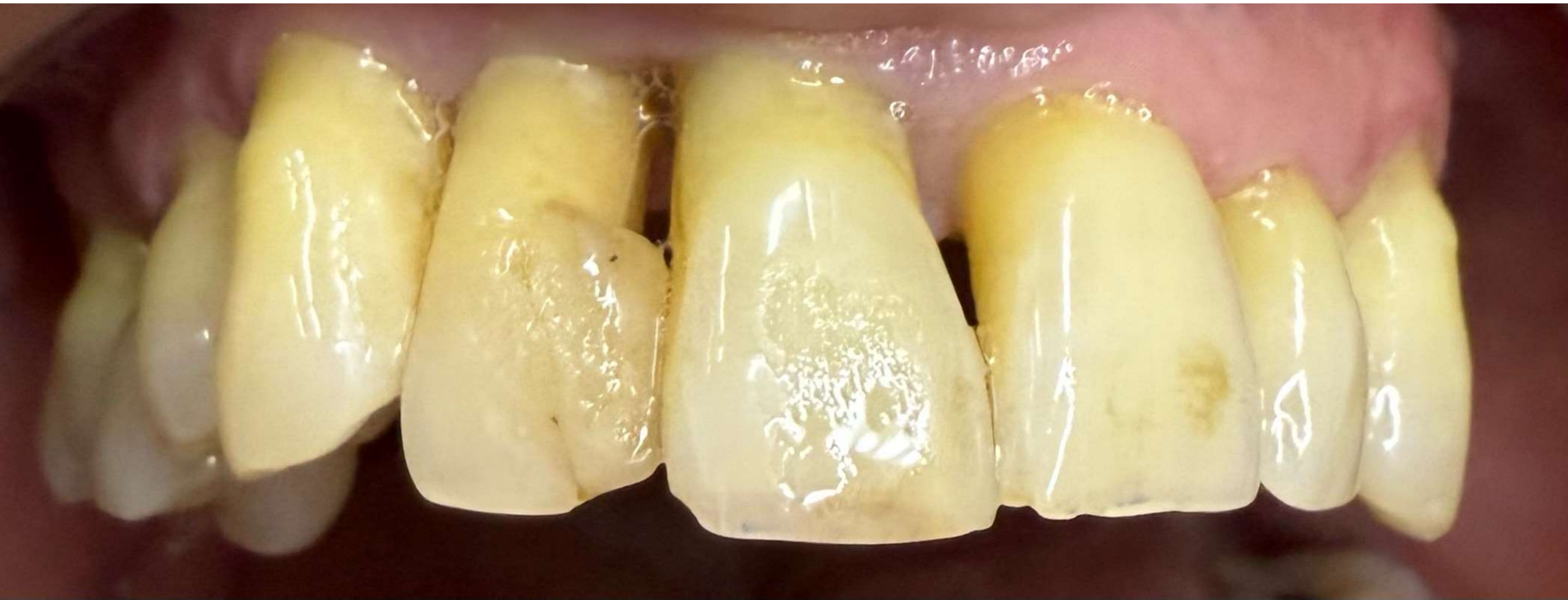


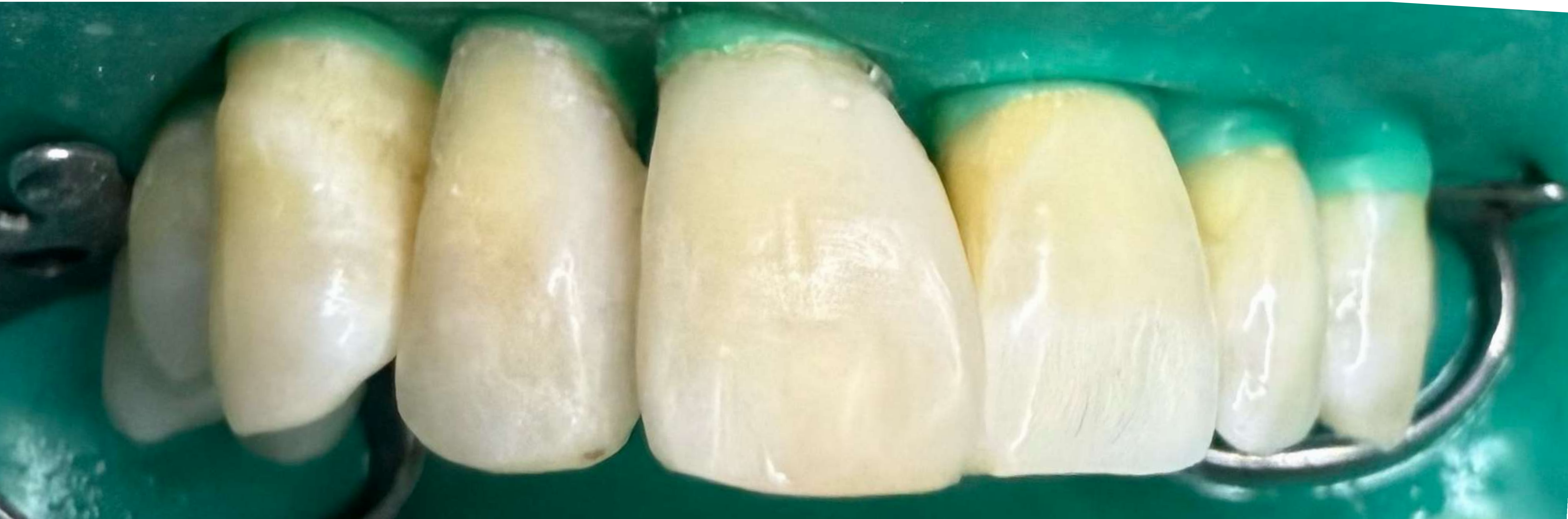


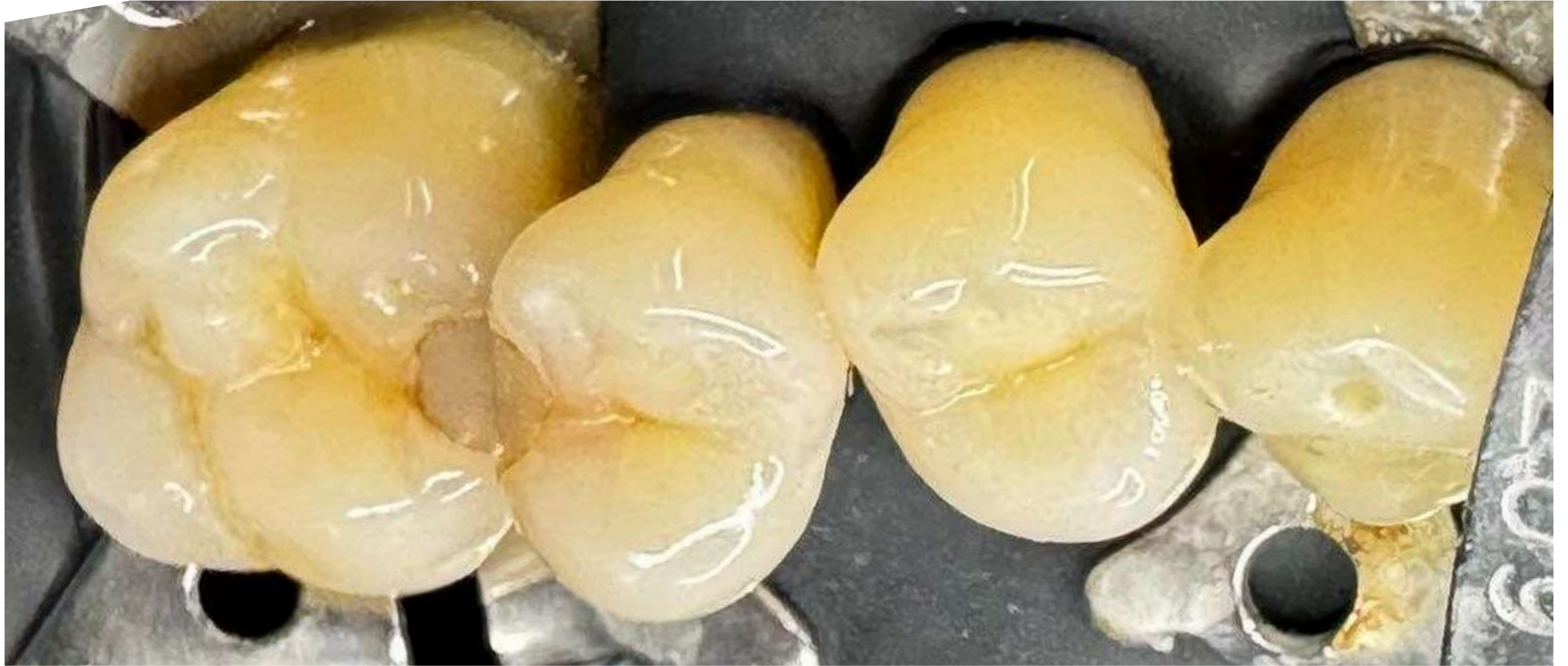


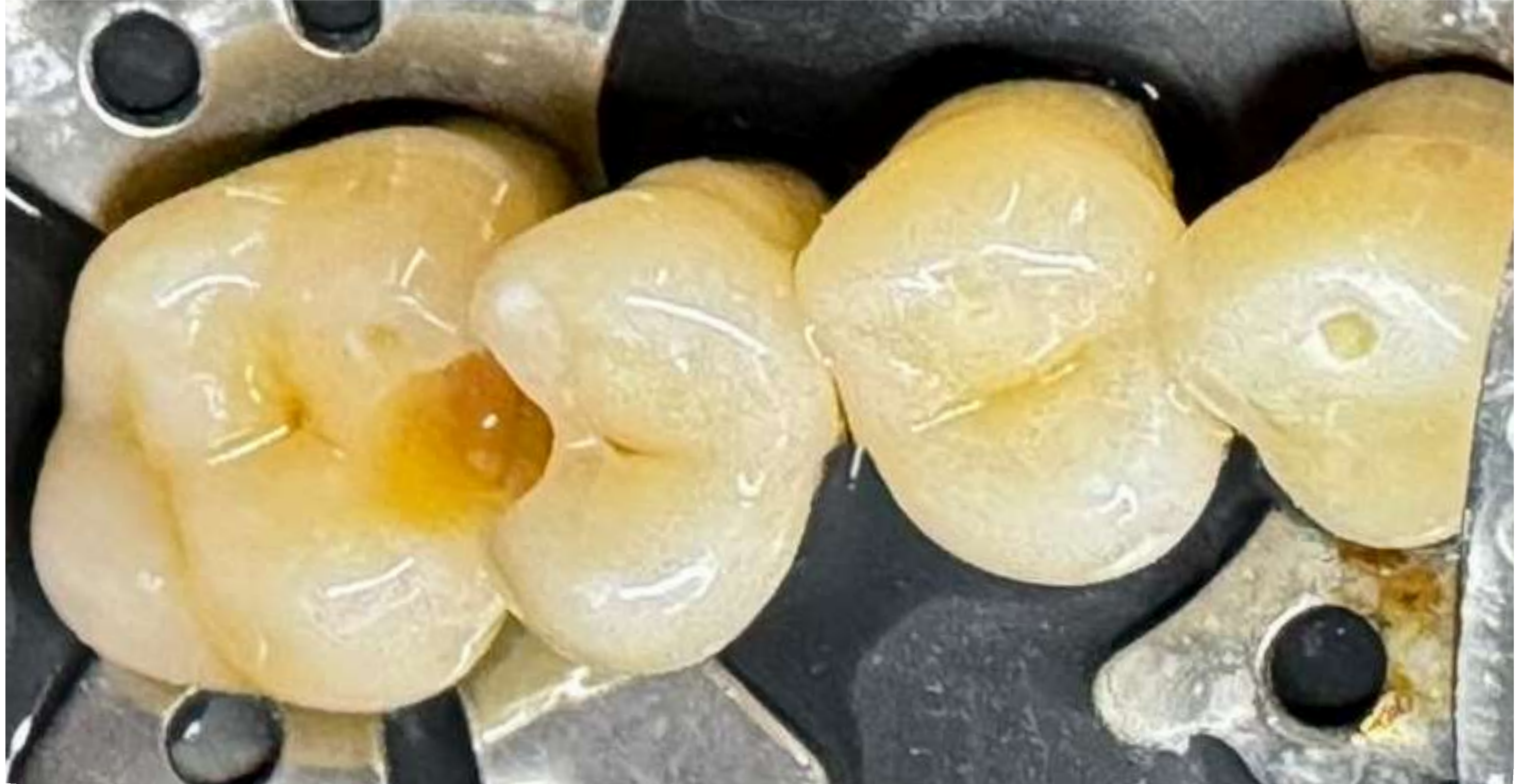


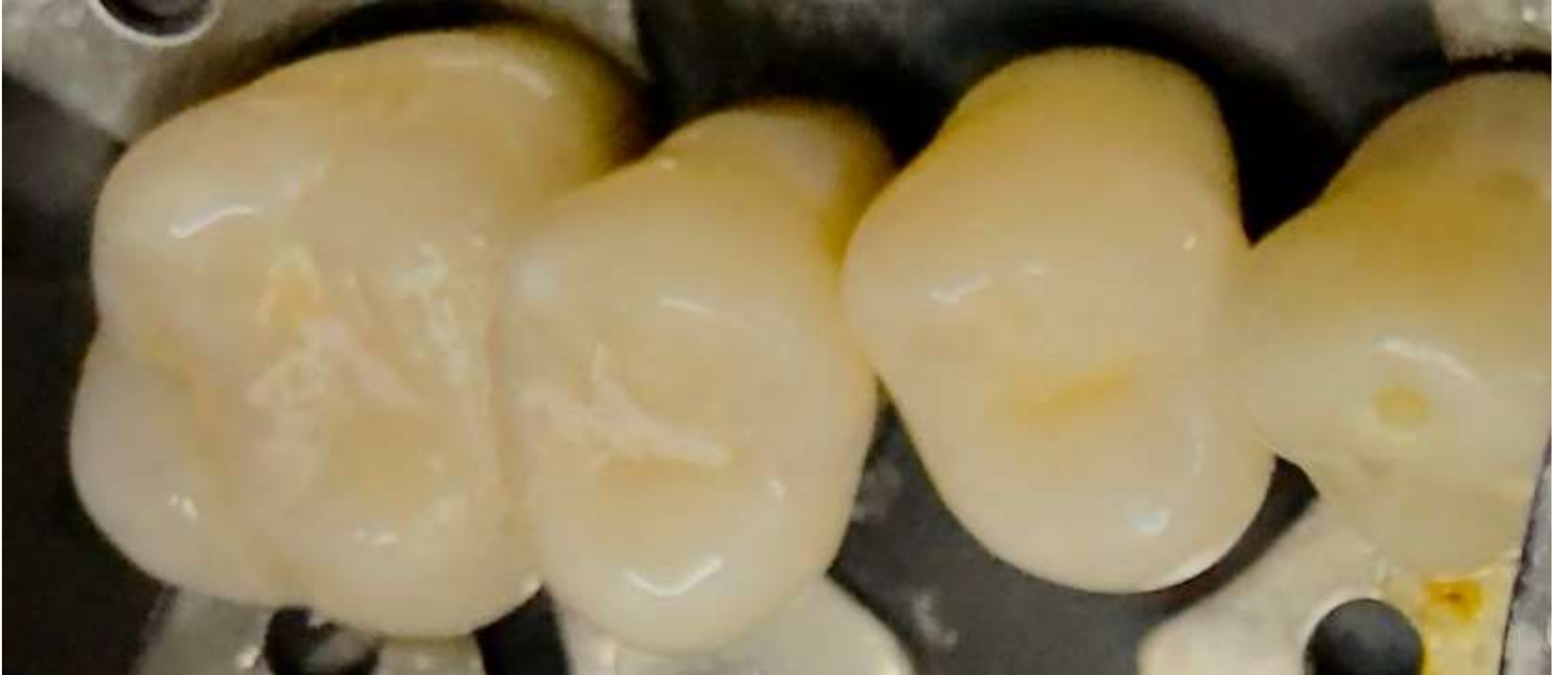


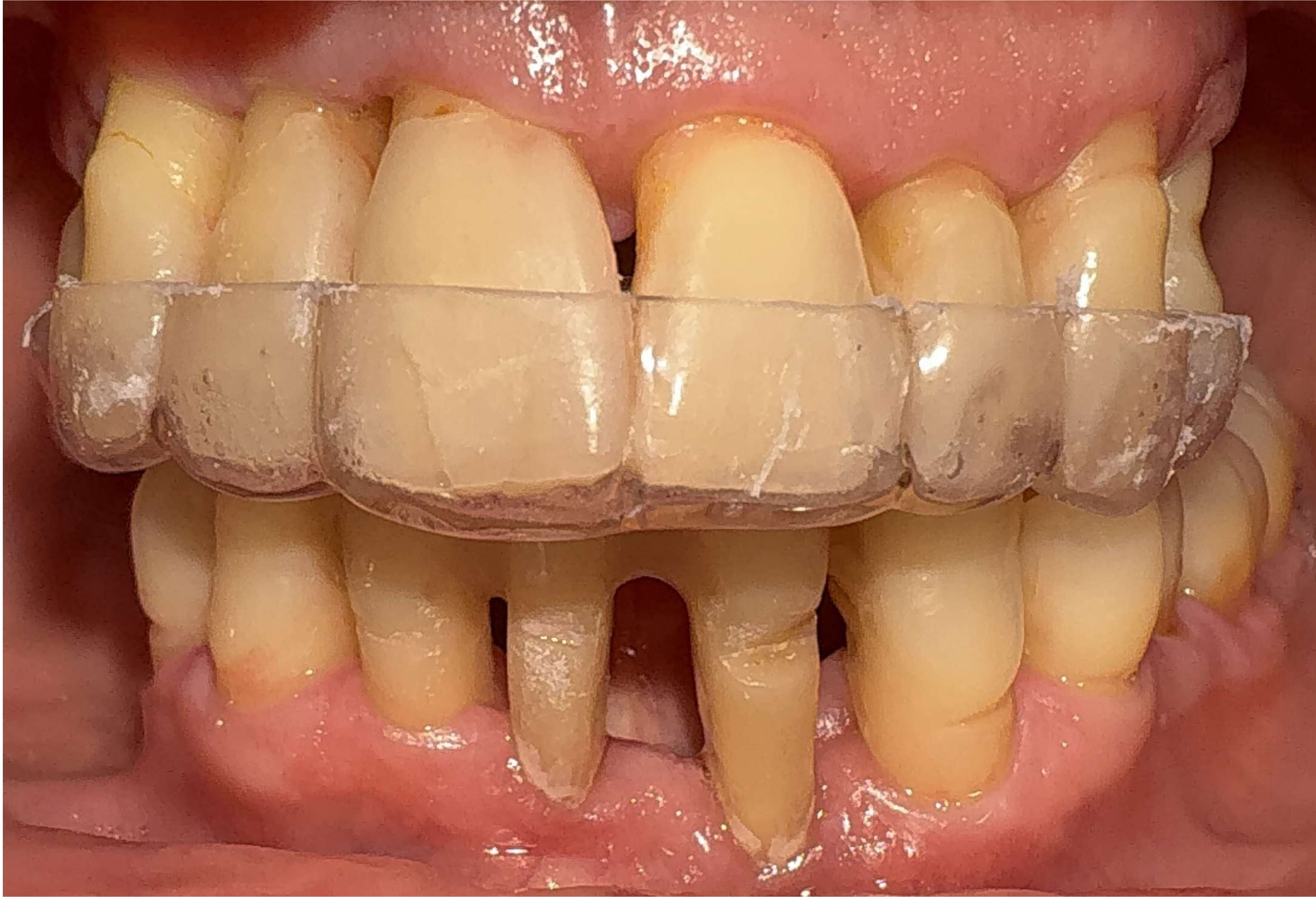




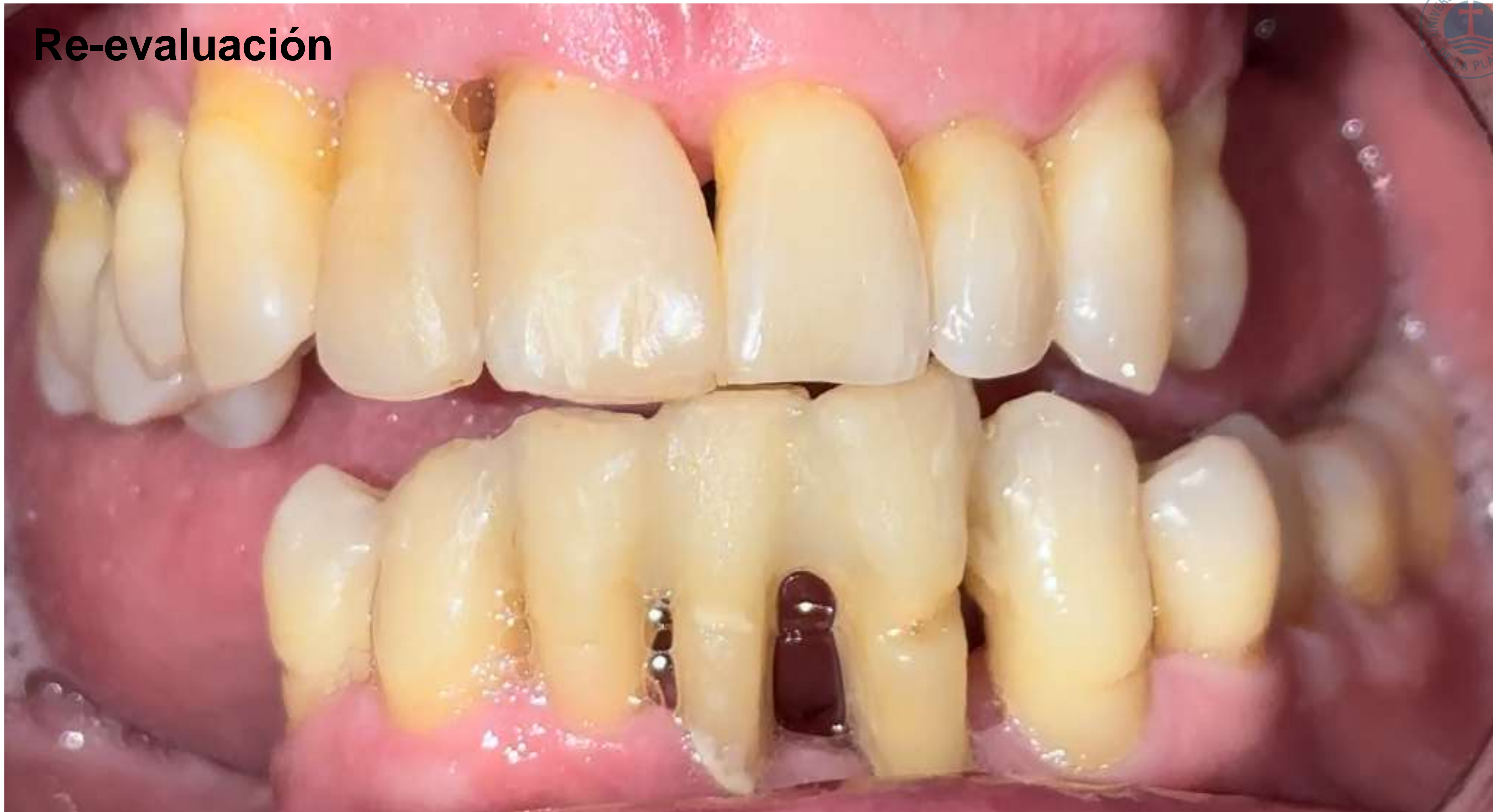Re-evaluación

Índice de O'Leary: 60%

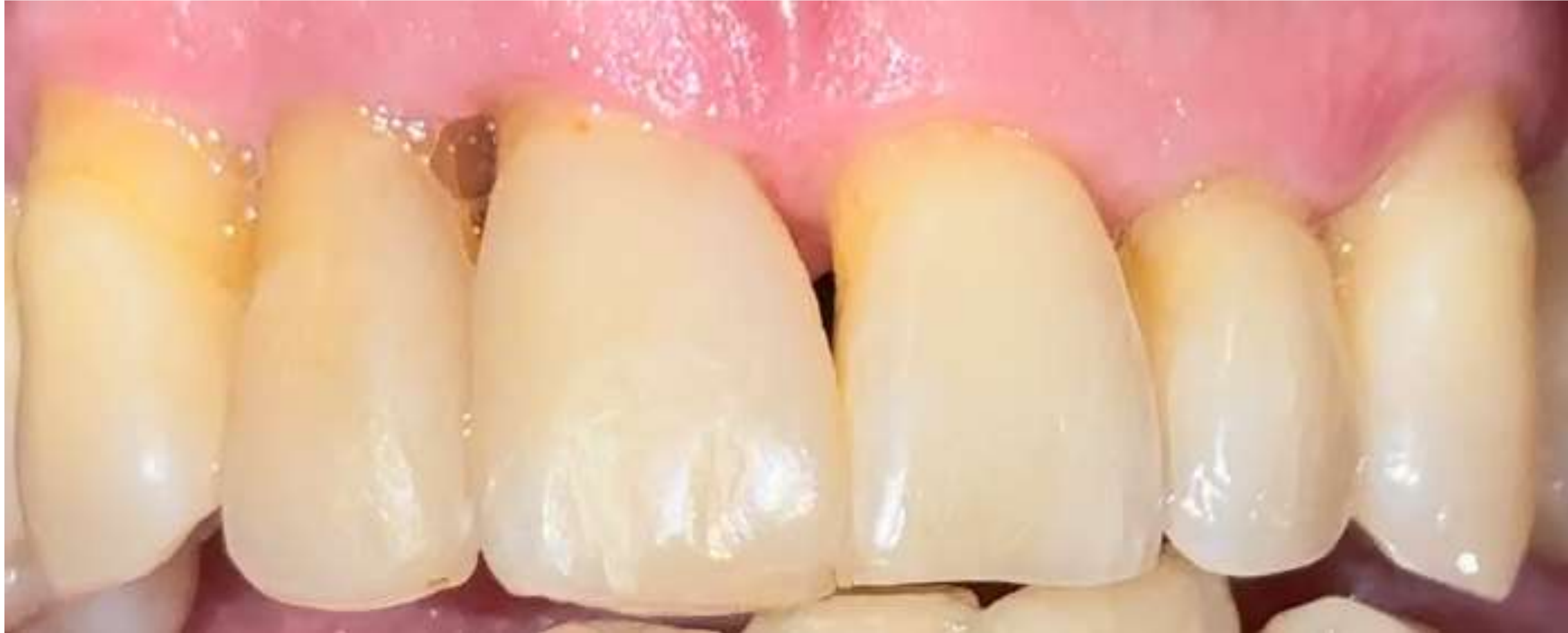Bolsas residuales menores a 5 mm

Re-evaluación

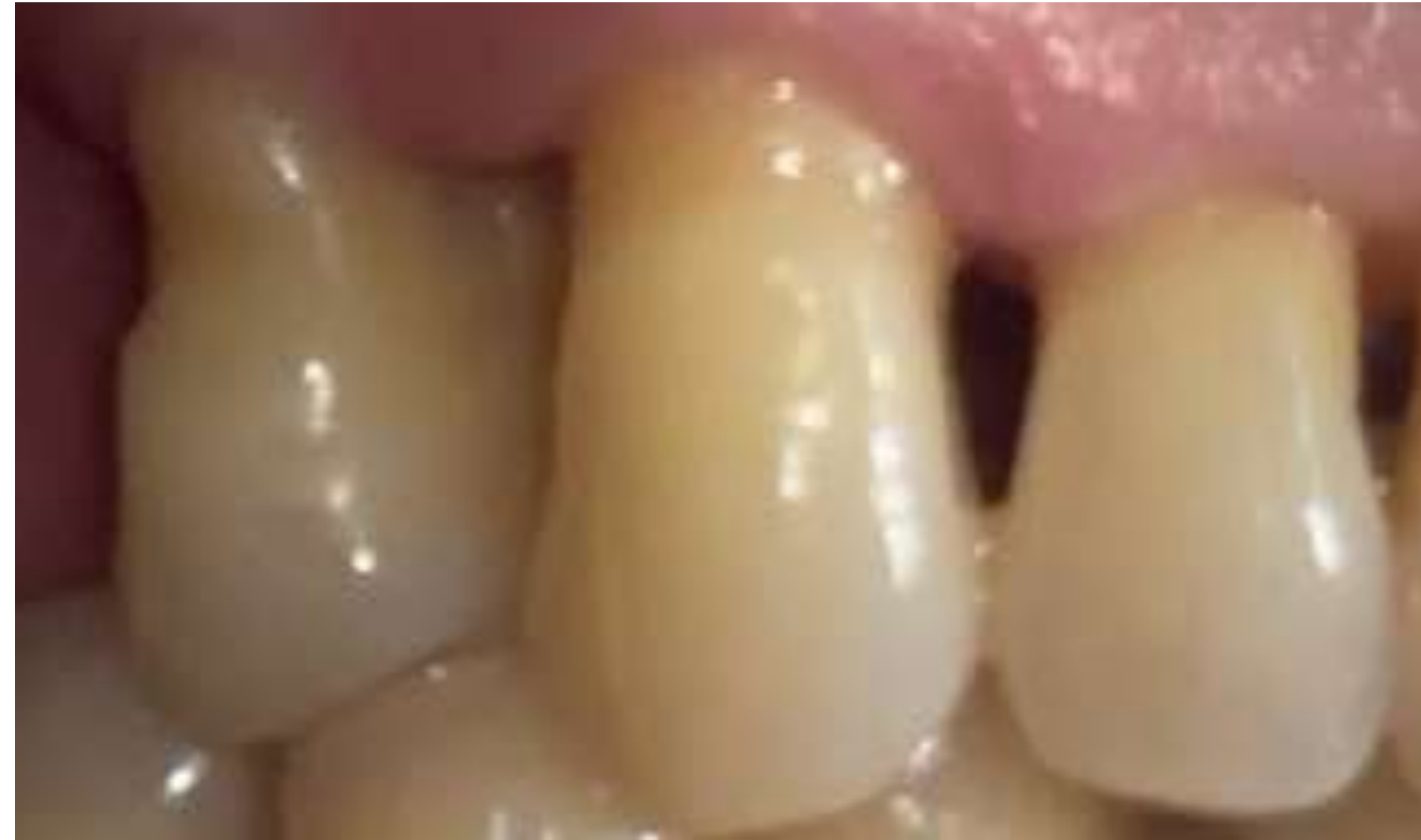
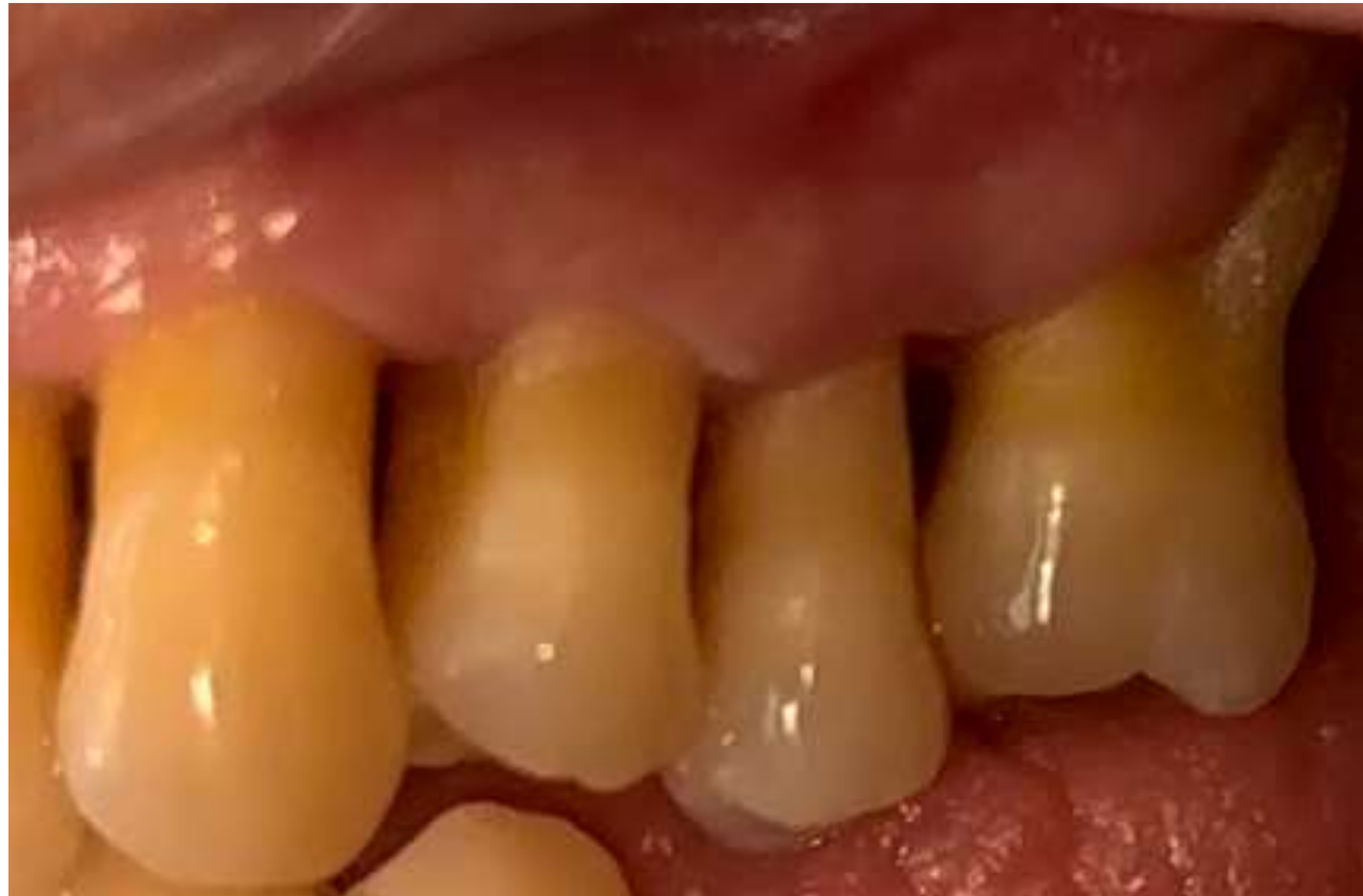
Re-evaluación

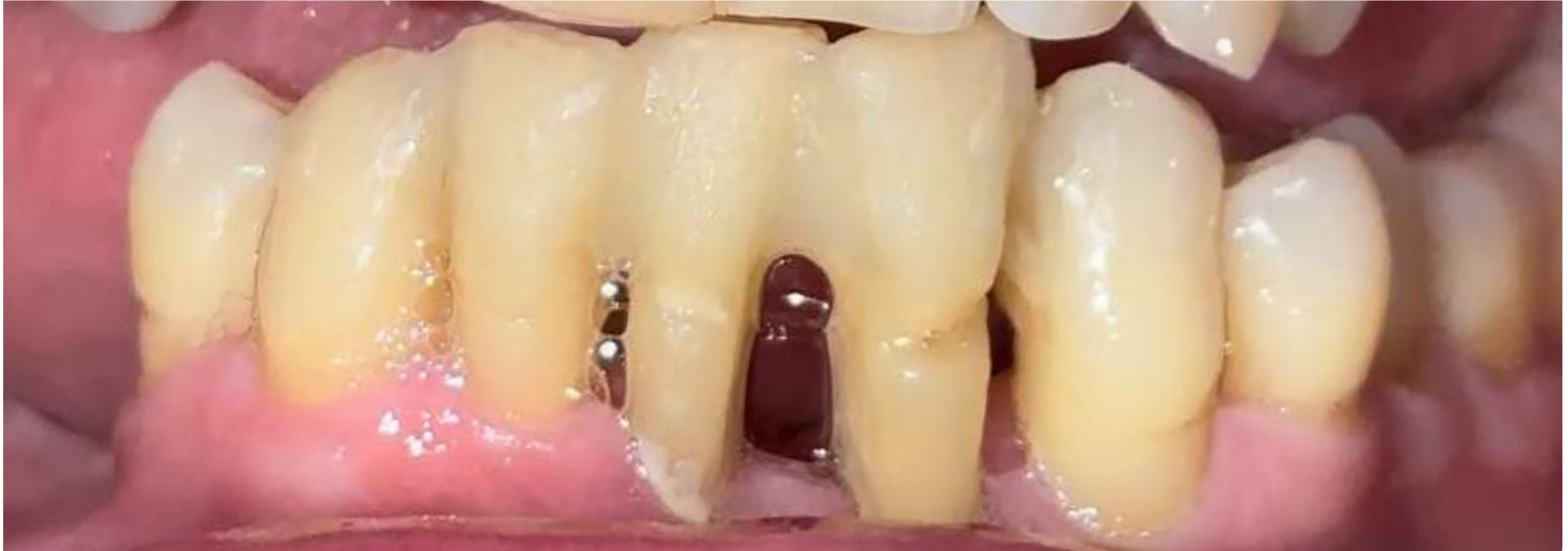6	2
5	
3	3
2	



Re-evaluación



Re-evaluación





Plan de tratamiento

Terapia periodontal de soporte

Mantenimiento periodontal cada 3 (tres) meses.



Plan de tratamiento

Terapia complementaria

Cirugía periodontal regenerativa

Colocación de implantes



Plan de tratamiento

Terapia restauradora

Restauración definitiva de lesiones de caries inactivadas

Restauración de coronas sobre implantes

Gracias por su atención.